ADDRESS

Timisoara, Romania
Gospodarilor Street, nr. 42
Tel: +4-0256-439441
cod 300778
e-mail: boiaeugen@yahoo.com

JURNALUL PEDIATRULUI – Year XVIII, Vol. XVIII, Nr. 71-72, july-december 2015
www.jurnalulpediatrului.ro
ISSN 2065 – 4855

REVISTA SOCIETĂŢII ROMÂNE DE CHIRURGIE PEDIATRICĂ
www.srcp.ro

CONTENTS

1. THYROID DISORDERS IN CHILDREN, ADOLESCENTS AND YOUNG ADULTS IN MUREŞ COUNTY (ROMANIA): A 25 YEARS RETROSPECTIVE STUDY
Zahan Ancuța Elena, Căpraru Oana-Maria, Borda Angela, Nechifor Boilă Adela, Otilia Mărginean, Pașcanu Ionela.....3

2. CHARACTERISTICS OF PEDIATRIC TUBERCULOSIS IN A HIGH ENDEMIC AREA
Elena Danteş, Ariadna Petronela Fildan, Adriana Socaci, Raluca Railanu, Emanuel Tudorache, Cristian Oancea.....10

3. AORTIC COARCTATION IN INFANTS AND CHILDREN – DIAGNOSE, TREATMENT AND PROGNOSIS
Gabriela Doroş, Anca Popoiu, Cristina Olariu, Alexandra Popescu, Ramona Olteanu, Raluca Isac, Mihai Gafencu.....16

4. CLINICAL ASPECTS IN EPSTEIN-BARR AND CYTOMEGALIC VIRUS CO-INFECTION IN CHILDREN
Simona Dumitra, Carmen Crişan, Luminița Pilat.....20

5. NEONATES AND BLOOD TRANSFUSIONS
Mihaela Demetrian, Constantin Ilie, Anca Panaitescu, Georgeta Grecu, Andra Pirnuta.....24

6. THE NEED FOR VENTILATORY SUPPORT AND SURFACTANT ADMINISTRATION IN PREMATURE INFANTS WITH NEONATAL RESPIRATORY DISTRESS
Andreea Fratila, Daniela Iacob, C. Ilie.....29

7. SEVERE CASES OF PEDIATRIC TUBERCULOSIS
Ariadna Petronela Fildan, Doina Tofolean, Claudia Toma, Emanuela Tudorache, Elena Dantes.....33

8. LAPAROSCOPIC CHOLECYSTECTOMY IN CHILDREN – PRELIMINARY EXPERIENCE
RE Iacob, MC Popoiu, VL David, DV Vasilie, Corina Stanciulescu, Lavinia Stretcu, Alexandra Nyiredi, ES Boia.....38

9. ADRENOGENITAL SYNDROME: POSITIVE DIAGNOSIS, EVOLUTION AND PROGNOSIS
Mariana Boia, Aniko Manea, Nicoleta Mutica, Ioana Micle, Otilia Marginean.....41

10. ABNORMAL UTERINE BLEEDING IN ADOLESCENT FEMALES
Marius Gliga, Camelia Gliga, Maximilian Gliga.....44

11. DIET ANALYSIS IN OBESE CHILDREN
Raluca-Monica Pop, Ionela Pașcanu.....48

12. ADRENOLEUKODYSTROPHY – THE DIAGNOSTIC AND THERAPEUTIC CHALLENGES
Cristina Ghervan, Codruța Nemeș, Jacques Young, Ana Valea, Alina Silaghi, Liviu Ghervan.....52

13. ENDOCRINE ABNORMALITIES IN CHILDREN WITH OBSTRUCTIVE SLEEP APNEA
Marcovici Tamara, Giorgiana Brad, Delia Nicoara, Maria Puiu, Maria Papa, Alina Grecu.....60

14. UP-TO-DATE CLASSIFICATION AND TREATMENT IN OSTEOGENESIS IMPERFECTA
Camelia Gliga, Ionela Pașcanu, Marius Gliga, Maximilian Gliga.....64

15. FEATURES OF THE ENDOCRINE-METABOLIC PLURIMALFORMATIVE SYNDROME
Mariana Boia, Aniko Manea, Oana Bilav.....68

16. MANAGEMENT OF CRANIPHARINGIOMAS IN CHILHOOD
Otilia Marginean, Giorgiana Brad, Ramona Stroescu, Daniela Chiru,
Oana Belei, Olariu Laura, Cristun Lucian Ioan, Marioara Boia.....72

17. ERATUM.....76

MANUSCRIPT REQUIREMENTS.....78

THYROID DISORDERS IN CHILDREN, ADOLESCENTS AND YOUNG ADULTS IN MUREŞ COUNTY (ROMANIA): A 25 YEARS RETROSPECTIVE STUDY

Zahan Ancuța Elena[1,2], Căpraru Oana-Maria[2,3], Borda Angela[1,], Nechifor Boilă Adela[1,4], Otilia Mărginean[5], Pașcanu Ionela[2,3]

Abstract

Background: Thyroid disease in children, adolescents and young adults (TDCA) is dominated by thyroid nodules, toxic multinodular goiter, Graves' disease, autoimmune thyroiditis and malignant thyroid tumors with origin in follicular cell or parafollicular C cells of the thyroid gland. The aim of our study was to evaluate the incidence of the TDCA in the last 25 years in our institution and the pathological characteristics of papillary thyroid carcinoma (PTC), with special emphasis on the comparison of the pathologic features of tumor aggressiveness between pediatrics and adults patients with PTCs.

Material and methods: We performed a retrospective, cohort study on 101 cases of TDCAs (patients < 20 years old), registered in the Department of Pathology, Tîrgu-Mureş Emergency County Hospital between 1990 and 2014.

Results: One hundred and one patients were identified, 90 girls and 11 boys, female to male ratio was 7:1 and mean age at diagnosis was 17.57 ± 1.0 years. A significant increase in the incidence of malignant thyroid tumors of follicular cell origin, was observed between 2004-2014 as compared to the period between 1990-2003 (70.6 *versus* 29.4%). On the other hand, the incidence of the benign thyroid diseases was characterized by a statistically significant decrease in the last decade (66.8% *versus* 33.2%, p<0.001). As we expected, PTC accounted for most of the cases of malignant thyroid tumors of follicular cell origin (n=16/17, 94.1%). The most common PTC variant was conventional PTC (CPTC) (62.5%). The most common benign thyroid disease was nodular goiter (45.5%), followed by follicular adenoma (19.8%). The autoimmune thyroid diseases were present in 13 cases - Hashimoto thyroiditis 9 cases (8.9%) and Graves' disease 4 cases (4%). The comparison between the pediatric and the adult thyroid cancer patients showed that children had higher rates of larger primary tumors (19.38 ± 9.729 mm versus 15.77 ± 0.8265 mm, p-0.005), a higher incidence of multifocality (43.75% versus 29.5%, p - 0.002), a more significant extrathyroidal extension (37.5% versus 19.8%, p- 0.002) and a more important lymph node involvement (25% versus 7.7%, p- 0.007).

Conclusion: The incidence of TDCA has revealed significant changes in our institution over the last 25 years. The incidence of malignant thyroid tumor of follicular cell origin has increased, while the incidence of the benign thyroid disease has significantly decreased over the study period. In our institution, the pediatric thyroid cancer has a more advanced stage and shows a more extensive disease at the time of diagnosis than adulthood thyroid cancer.

Key words: thyroid disease, children, papillary thyroid carcinoma, extensive disease

Introduction

Thyroid disease in children, adolescents and young adults (TDCA) is dominated by thyroid nodules, with a higher malignancy rate compared to adults, toxic multinodular goiter, Graves' disease, autoimmune thyroiditis and malignant thyroid tumors with origin in follicular cell or parafollicular C cells of the thyroid gland [1-4].

Thyroid cancer has become the fifth most common cancer in children aged 0–14 years [5] and the most common cancer in adolescents and young adults [6] with a significant increasing incidence in the last four decades, as reported by many studies around the world [7-11].

Factors attributed to the increased incidence include iodine deficiency, genetic predisposition (RET mutations) and ionizing radiations. The latter represent a proven risk factor for thyroid malignancies as confirmed by the sharp increase in the thyroid cancer after the Chernobyl disaster [12-20]. Many authors have also described the role of cytokines and genes (e.g. VEGF, TGF and EGF) during tumor development [21, 22].

[1]Department of Histology, University of Medicine and Pharmacy of Tîrgu-Mureş, Romania
[2]Department of Endocrinology, Emergency County Hospital, Tîrgu-Mureş, Romania
[3]Department of Endocrinology, University of Medicine and Pharmacy of Tîrgu-Mureş, Romania
[4]Department of Pathology, Emergency County Hospital, Tîrgu-Mureş, Romania
[5]Pediatric Department, University of Medicine and Pharmacy, Timişoara, România
E-mail: ancutza_ct@yahoo.com, oanacapraru@yahoo.com, aborda2001@yahoo.com, adelanechifor@yahoo.com, iopascanu@gmail.com, omarginean@ymail.com

Papillary thyroid carcinoma (PTC) is the most common histological type (60–97%) observed in childhood patients with both sporadic and radiation-induced thyroid carcinoma [17, 18, 20].

Pediatric thyroid cancer tends to be more advanced at the time of diagnosis and has a higher rate of recurrence than thyroid cancers in seen in adults, nevertheless, pediatric patients have a better prognosis and a significantly lower mortality rates than adult patients [23-26].

The aim of our study was to evaluate the incidence of the TDCA in the last 25 years in our institution and the pathological characteristics of PTC, with special emphasis on the comparison between the pathological features of tumor aggressiveness in pediatric and adult patients with PTC.

Materials and methods

Database and cases definition

We performed a 25 years, retrospective, cohort study on 101 cases of TDCAs (patients < 20 years old) registered in the Department of Pathology, Tîrgu-Mureș Emergency County Hospital between January 1990 and December 2014.

Clinicopathological data on the study cases were retrieved from database registers and pathological reports. The following variables were included when analysing the incidence and the pathological characteristics of TDCA cases: age at diagnosis, gender, surgical procedure and type of thyroid disease. For the malignant thyroid tumors we evaluated the tumor histological type, size, multifocality (unilateral or bilateral), extrathyroidal extension and lymph node involvement.

The type of the surgical procedure was also recorded: lobectomy with or without isthmectomy, subtotal thyroidectomy, total thyroidectomy and total thyroidectomy with central or lateral neck compartment dissection.

The histophatological types of TDCA included: benign thyroid disorders (nodular goiter, follicular adenoma, Hashimoto thyroiditis and Graves's disease), tumors of uncertain malignant potential and malignant thyroid tumors of follicular cell origin.

The malignant thyroid tumors of follicular cell origin were referred as papillary thyroid carcinomas (PTCs), follicular thyroid carcinomas (FTCs), poorly differentiated thyroid carcinomas (PDTCs) and anaplastic thyroid carcinomas (ATCs). The diagnosis of PTC was exclusively based on nuclear features (Figure 1A): enlargement, overlapping, irregularity of the nuclear contours, grooves, clearing or a ground glass appearance and nuclear pseudoinclusions. Conventional PTC had a characteristic papillary architecture that was pure or admixed with a variable proportion of follicles. Tumors defined as follicular variant of PTC were composed of small to medium sized, irregularly shaped follicles, with characteristic PTC nuclear changes in most of the cells lining these follicles and virtually no papillary structures. The diagnosis of other tumors was made in accordance to the WHO criteria [25].

The 2009 TNM staging system (tumor size, extrathyroidal extension, lymph node metastasis, distant metastasis) was applied for all the cases included in the study [26].

Extrathyroidal extension was defined as tumor penetration through the thyroid capsule into the adjacent tissues, with invasion into the immediate perithyroidal soft tissues or sternothyroid muscle (TNM stage T3 tumors) (Figure 1B) [26].

Multifocality was defined as the presence of two or more isolated/non-contiguous tumor foci in the resected thyroid gland [25].

The lymph node involvement was considered positive if at least one positive lymph node was present in the lymph nodes resected during surgery.

The pathological features of tumor aggressiveness in pediatric patients were compared to a cohort of 608 adults with PTC also diagnosed in our institute in the last 25 years.

In order to analyze the incidence, clinical and pathological features of TDCA, we subdivided the total series in two main groups, according to the time of diagnosis: group one (1990-2003) and group two (after 2004). The cut-off year of 2004 has been chosen in accordance to the introduction of the new WHO classification of Endocrine Tumors [25].

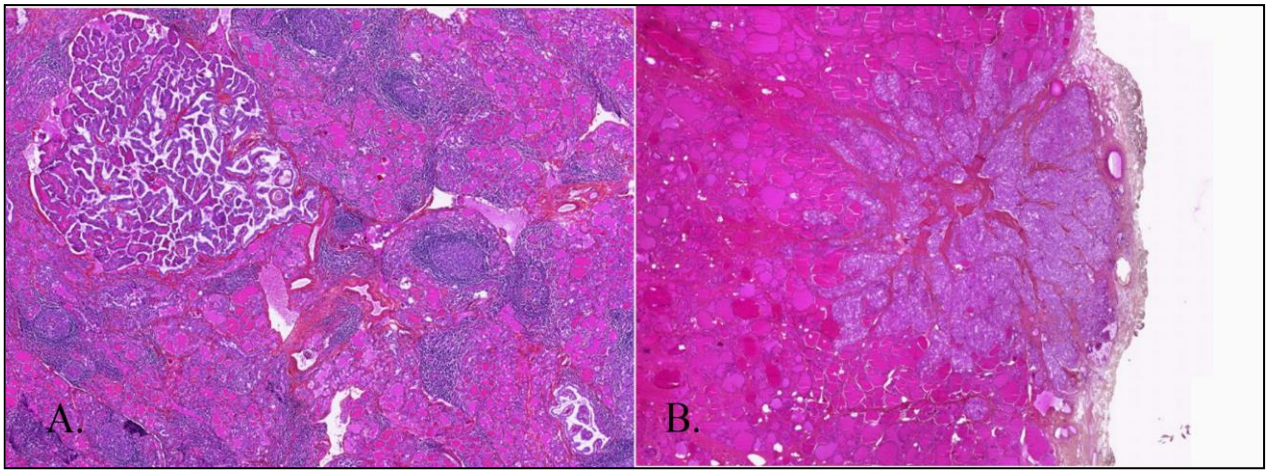

Figure 1: Intrathyroidal versus extrathyroidal papillary thyroid carcinoma: a multifocal, intrathyroidal conventional, papillary thyroid carcinoma case (A); extrathyroidal extension, defined as tumor penetration into the adjacent adipose or muscular tissues (B).

Data analysis

Statistical analysis was performed using the Statistical Package for Social Sciences (SPSS, version 20, Chicago, IL, USA). Data were labelled as nominal or quantitative variables. Nominal variables were characterized by means of frequencies. Quantitative variables were tested for normality of distribution using Kolmogorov-Smirnov test and were described by mean ± standard deviation or median and percentiles (25%; 75%), whenever appropriate. The frequencies of nominal variables were compared with a chi-square test. Differences in the mean or median between groups were analyzed using the *t* test and ANOVA test. The level of statistical significance was set at p<0.05.

Results

From a total of 4890 tumoral and non-tumoral thyroid lesions registered in our department over the last 25 years, 101 (2.1%) were TDCA.

Regarding the surgical procedure, total thyroidectomy, subtotal thyroidectomy, lobectomy and total thyroidectomy with central or lateral neck compartment dissection were performed in 45 (44.5%), 20 (19.8%), 34 (33.8%) and 2 (1.9 %) cases, respectively.

The majority of TDCA cases occurred in females (87.2%), with the female to male ratio of 7:1. The mean age at diagnosis was 17.57 ± 1.0 years-old, ranging from 5 to 19 years-old with no statistically significant difference by gender group.

The incidence of various TDCA is shown in Table 1. A significant increase in the incidence of malignant thyroid tumors of follicular cell origin was observed between 2004-2014 as compared to the period between 1990-2003 (70.6 v*ersus* 29.4%) On the other hand, the incidence of the benign thyroid diseases was characterized by a statistically significant decrease in the last decade (66.8% *versus* 33.2%, p<0.001) (Table I).

The most common benign thyroid disease was nodular goiter (45.5%), followed by follicular adenoma (19.8%). The autoimmune thyroid diseases were present in 13 cases - Hashimoto thyroiditis 9 cases (8.9%) and Graves' disease 4 cases (4%) (Table I).

Table I. Incidence and histophatological characteristics of 101 TDCAs

Histophatological types of TDCAs	No. of cases Total (%)	No. of cases 1990-2003 (%)	No. of cases 2004-2014 (%)	p
Benign thyroid diseases	79	53 (66.8)	26 (33.2)	<0.001
Nodular Goiter	46 (45.5)			
Follicular adenoma	20 (19.8)			
Hashimoto Thyroiditis	9 (8.9)			
Graves' Disease	4 (4)			
Malignat thyroid tumors with follicular cells origin	17 (16.8)	5 (29.4)	12 (70.6)	<0.001
Papillary thyroid carcinoma	16			
Poorly differentiated thyroid carcinoma	1			
Thyroid tumors of uncertain malignant potential	5 (5)	1(20)	4 (80)	<0.001
Total TDCA	101	59 (31.7)	42 (68.3)	

As we expected, PTC accounted for most of the cases of malignant thyroid tumors of follicular cell origin (n=16/17, 94.1%). The most common PTC variant was conventional PTC (CPTC) (62.5%), followed by follicular variant of PTC (FVPTC) (37.5%). The incidence and clinicopathologic characteristics of different histological variants of PTC cases are summarized in Table II. Despite the smaller mean tumor size of CPTC versus FVPTC cases (15.77 ± 0.8265 mm versus 19.02±0.8622 mm, p-0.02), the other pathological features of tumor aggressiveness were more prevalent among CPTC: extrathyroidal extension (100 % versus 0%, p<0.001), lymph node involvement (100% versus 0%, p<0.001) and multifocality (85.7 % versus 14.3, p-0.001).

The comparison between the pediatric and the adult thyroid cancer patients showed that children had higher rates of large primary tumors (19.38 ± 9.729 *versus* 15.77 ± 0.8265, p-0.005), a higher incidence of multifocality (43.75% *versus* 29.5%, p - 0.002), a more significant extrathyroidal extension (37.5% *versus* 19.8%, p- 0.002) and a more important lymph node involvement (25% versus 7.7%, p- 0.007) as compared to adults (Table III).

Table II. Clinicopathologic characteristics of classical/conventional papillary thyroid carcinoma cases and follicular variant.

Factors	CPTC (%)	FVPTC (%)	p
Total	10 (62.5)	6 (37.5)	
Mean age (years-old)	17.8 ± 1.8	17.2 ± 2.2	0.477
Female	8 (80)	4 (66.6)	0.402
Tumor size (mean, mm)	15.77± 0.8265	19.02±0.8622	0.02
≤ 10	1 (10)	1 (16.7)	0.028
11-20	5(50)	3 (50)	
21-40	3 (30)	2 (33.3)	
>40	1 (10)	0 (0)	
pT stage[a]			<0.001
pT1a	1 (10)	1 (16.7)	
pT1b	2 (20)	4 (66.6)	
pT2	1 (10)	1 (16.7)	
pT3	6 (60)	0 (0)	
Lymph node involvement	4 (100)	0 (0)	<0.001
Multifocality	6 (85.7)	1 (14.3)	0.001
Extrathyroid extension	6 (100)	0 (0)	<0.001

Legend: papillary thyroid carcinoma- PTC, conventional PTC-CPTC, follicular variant of PTC – FVPTC
[a] - TNM Classification of malignant tumors.7th Edition ed. Springer (2009).

Table III. Pathological characteristics in pediatric and adult patients with PTC.

Factors	PTC in pediatric patients (%)	PTC in adult patients (%)
Total	16	608
Tumor size (mean, mm)	19.38± 9.729	15.77± 0.8265
p		0.005
Lymph node involvement	4 (25)	46 (7.7)
p		0.007
Multifocality	7 (43.75)	179 (29.5)
p		0.002
Extrathyroid extension	6 (37.5)	120 (19.8)
p		0.002

Legend: papillary thyroid carcinoma- PTC

Discussions

Our study revealed important changes in the incidence of various TDCA in our institution over the last 25 years (1990-2014). The incidence of malignant thyroid tumors of follicular cell origin was characterized by a statistically significant increasing trend after the year 2004 as compared to the previous period in our institution. Similar results have been reported in many countries around the world, and especially in countries from Europe and North America [7-10].

Many factors can be attributed to the increasing incidence of malignant thyroid tumors. Some well-known risk factors for follicular-derived thyroid carcinomas, like the ionizing radiations (radiotherapy, fallouts, diagnostic X-rays), lifestyle habits (overweight, low iodine intake), some environmental pollutants (dioxins, polychlorinated biphenyls etc.) are also present in our region.

The thyroid gland in children is most sensitive to ionizing radiations [12], which explains the increasing proportion of thyroid cancer diagnosed in older children who underwent radiation therapy for their first primary tumor [13-15,29,30].

Taylor A.J *et al*. showed that in a cohort of 17,980 patients, followed for an average of 17.4 years, eighty-eight percent of thyroid carcinomas were found in patients undergoing radiotherapy for primary pathologies in the cervical region. The risk of thyroid carcinoma was higher in patients treated for Hodgkin's disease (RR 3.3—IC: 1.1–10.1) and non-Hodgkin lymphoma (RR 3.4—IC: 1.1–10.7) [16].

Our region was affected in April 1986 by the Chernobyl nuclear power plant disaster, but further research is still needed to prove the involvement of the radioactive particles in the initiation and progression of TDCA in our country.

Exposure to ionizing radiation during and after the Chernobyl accident increased the risk for the development of well-differentiated thyroid cancer in those exposed in childhood and adolescence, as demonstrated in many studies [16-19].

In 2006, Cardis *et al*. indicated that the number of thyroid cancer cases in children aged between 0 to 14 years, started to increase 4–5 years after the Chernobyl disaster and reached a peak at about 10 years, while for those aged 15 to 18 years, the peak was reached 15 years after exposure [18].

The incidence of the benign thyroid diseases (surgically treated) has significantly decreased in the last decade in our institution. We found that the most common benign thyroid disease was nodular goiter, followed by follicular adenoma. A possible explanation for this result is the fact that besides the mandatory use of iodized salt in our country since 2002, our region is still mildly iodine-deficient and multinodular goiter is still relatively frequent. A re-evaluation of the national program for the prevention and control of iodine deficiency in our country is mandatory.

In our study, the incidence of malignant thyroid carcinoma was 16.8% and the PTC was diagnosed in 94.1% cases, similar to the incidence from other reports [1-3]. CPTC was the most common variant of PTC in our study (46.9%), followed by FVPTC (45.6%), in accordance with other published studies [31].

Regarding the histological variant, many studies have shown that follicular variant of PTC is associated with a more favourable prognosis compared to the conventional PTC [32, 33].

In accordance to previous results, in our study, the conventional PTC revealed a higher rate of lymph node involvement, extrathyroidal extension, multifocality and more prevalent TNM T3 tumor stage, compared to the follicular variant.

Based on the data reported in scientific literature, regarding that pediatric thyroid cancer tends to be more advanced at the time of diagnosis and has a higher rate of recurrence than adulthood thyroid cancer [23-26], we have analysed the prevalence of the pathologic features of tumor aggressiveness between these two groups of patients.

In our study, children with PTC presented with more extensive disease as compared to adults with PTC. Lymph node involvement at diagnosis was observed in 25% of children compared to 7.7% of adults. Similar studies have shown that the lymph node involvement at diagnosis is seen in 40% to 90% of children compared to 10% to 50% of adults [23-25].

The prevalence of extrathyroidal extension in pediatric patients with PTC was 37.5%, significantly higher than that in adult PTC patients where it was only 19.8%. Extrathyroid extension is an independent factor predicting a poor prognosis, an important risk factor used in TNM based staging system [4, 28].

Multifocal disease was more common in children than adults and is seen in about 43.75% of childhood PTC cases. In a recent retrospective review of 150 pediatric patients, Lee YA *et al*. demonstrated that the recurrence was higher in pediatric patients with multifocal papillary thyroid cancer than adult patients [26]. Other studies have shown that multifocality was an independent risk factor for PTC recurrence, metastasis or disease-specific mortality [23, 33, 34].

An important limitation to our study is the lack of data regarding the mortality and/or disease-specific survival rates in pediatric patients with PTC. However, we succeeded to determine the incidence and the pathological characteristics in our population over a period of 25 years.

Conclusions

In summary, the incidence of TDCA has revealed significant changes in our institution over the last 25 years. The incidence of malignant thyroid tumors of follicular cell origin has increased, while the incidence of the benign thyroid disease has significantly decreased over the period of the study. In our study, the follicular variant of PTC is associated with more favourable pathological characteristics as compared to conventional PTCs. In our institution, the pediatric thyroid cancer has a more advanced stage and shows a more extensive disease at the time of diagnosis than adulthood thyroid cancer.

Conflicts in interest

The authors declare that they have no conflicts of interest.

Acknowledgements

This paper is supported by the Sectorial Operational Programme Human Resources Development (SOP HRD), financed from the European Social Fund and by the Romanian Government under the contract number POSDRU/159/1.5/S/137390/.

References

1. Corrias A, Mussa A, Baronio F, Arrigo T, Salerno M, et al. Diagnostic features of thyroid nodules in pediatrics. Arch Pediatr Adolesc Med 2010; 164:714-9.
2. Hung W. Solitary thyroid nodules in 93 children and adolescents: a 35-year experience. Horm Res 1999; 52:15-8.
3. Mirshemirani A, Roshanzamir F, Tabari AK, Ghorobi J, Salehpoor FA. Thyroid nodules in childhood: a single institution experience. Iran J Pediatr 2010;20:91-6.
4. Scott A, Rivkees – Pediatric Endocrinology Fourth Edition- Chapter 12 - Thyroid Disorders in Children and Adolescents, 2014; 444-457.
5. Moon EK, Park HJ, OH CM, et al. Cancer incidence and survival among adolescents and young adults in Korea. PLoS One. 2014;9:e96088 .
6. Jung KW, Won YJ, Kong HJ, OH CM, Lee DH, Lee JS. Cancer statistics in Korea: incidence, mortality, survival, and prevalence in 2011. Cancer Res Treat. 2014;46:109–123.
7. J. Josefson and D. Zimmerman, “Thyroid nodules and cancers in children,” Pediatric Endocrinology Reviews, vol. 6, no. 1, pp. 14–23, 2008.
8. Holmes L, Jr, Hossain J, Opara F. Pediatric thyroid carcinoma incidence and temporal trends in the USA (1973-2007): race or shifting diagnostic paradigm? ISRN Oncol 2012; 906197.
9. Hogan AR, Zhuge Y, Perez EA, Koniaris LG, Lew JI, et al. Pediatric thyroid carcinoma: incidence and outcomes in 1753 patients. J Surg Res 2009;156: 167–72..
10. Vaisman F, Corbo R, Vaisman M. Thyroid carcinoma in children and adolescents –Systematic review of the literature. J Thyroid Res 2011;1-7.
11. Gary L. F., Steven G. W, Andrew J. B, et.al. Management guidelines for children with thyroid nodules and differentiated thyroid cancer. Thyroid 2015; Volume 25, Number 7, 716-759.
12. Sigurdson AJ, Ronckers CM, Mertens, et al. Primary thyroid cancer after a first tumor in childhood (the Childhood Cancer Survivor Study): A nested case-control study. Lancet 2005; 365:2014. which explains the increasing proportion of thyroid cancer diagnosed in older children who underwent radiation therapy for their first primary tumor.
13. J. A. Sipos and E. L. Mazzaferri, “Thyroid cancer epidemiology and prognostic variables,” Clinical Oncology, vol. 22, no. 6, pp. 395–404, 2010.
14. C. M. Ronckers, A. J. Sigurdson, A. C. Mertens et al., “Second primary thyroid cancer after a first childhood malignancy: a report from the Childhood Cancer Survivor Study,” in Proceedings of the American Association for Cancer Research, vol. 45, 2004, AACR Meeting abstract, Pediatric Oncology, No. 3113.
15. O. Catelinois, P. Verger, M. Colonna, A. Rogel, D. Hemon, and M. Tirmarche, “Projecting the time trend of thyroid cancers: its impact on assessment of radiation-induced cancer risks,” Health Physics, vol. 87, no. 6, pp. 606–614, 2004.
16. A. J. Taylor, A. P. Croft, A. M. Palace et al., “Risk of thyroid cancer in survivors of childhood cancer: results from the British childhood cancer survivor study,” International Journal of Cancer, vol. 125, no. 10, pp. 2400–2405, 2009.
17. Pacini F, Vorontsova T, Demidchik EP, Molinaro E, Agate L, Romei C, et al. Post-Chernobyl thyroid carcinoma in Belarus children and adolescents: comparison with naturally occurring thyroid carcinoma in Italy and France. J Clin Endocrinol Metab 1997;82: 3563–9.
18. Cardis E, Howe G, Ron E, Bebeshko V, Bogdanova T, Bouville A, et al. Cancer consequences of the Chernobyl accident: 20 years on. J Radiol Prot 2006;26:127–40.
19. Doina Piciu, Andra Piciu, Alexandru Irimie. Thyroid cancer in children: a 20-year study at a Romanian oncology institute. Endocrine Journal 2012, 59 (6), 489-496.
20. R. M. Tuttle, F. Vaisman, and M. D. Tronko, “Clinical presentation and clinical outcomes in chernobyl-related paediatric thyroid cancers: what do we know now? What can we expect in the future?” Clinical Oncology (Royal College of Radiologists), vol. 23, no. 4, pp. 268–275, 2011.
21. D. Vesely, J. Astl, P. Matucha, I. Sterzl, J. Betka, Serum levels of angiogenic growth factors in patients with thyroid gland tumors and parathyroid adenoma, Neuroendocrinol. Lett. 24 (2003) 417–419.
22. S.W. Moore, J. Appfelstaedt, M.G. Zaahl, Familial medullary carcinoma prevention, risk evaluation, and RET in children of families with MEN2, J. Pediatr. Surg. 42 (2007) 326–332.
23. Palmer BA, Zarroug AE, Poley RN, Kollars JP, Moir CR. Papillary thyroid carcinoma in children: risk factors and complications of disease recurrence. J Pediatr Surg. 2005;40:1284–1288.
24. Zaydfudim, V., Feurer, I. D., Griffin, M. R., & Phay, J. E. (2008). The impact of lymph node involvement on survival in patients with papillary and follicular thyroid carcinoma. Surgery, 144, 1070–1077; discussion 1077–1078.
25. Okada, T., Sasaki, F., Takahashi, H., et al. (2006). Management of childhood and adolescent thyroid

carcinoma: long-term follow-up and characteristics. Eur J Pediatric Eur J Pediatr Surg 2006; 16(1): 8-13.
26. Young Ah Lee, Hae Woon Jung, Hwa Young Kim, et al. Pediatric Patients With Multifocal Papillary Thyroid Cancer Have Higher Recurrence Rates Than Adult Patients: A Retrospective Analysis of a Large Pediatric Thyroid Cancer Cohort Over 33 Years. J Clin Endocrinol Metab.2015; 100(4):1619–1629.
27. DeLellis RA, Lloyd RV, Heitz PU, Eng C. World Health Organization Classification of Tumours. Pathology and genetics of tumours of endocrine organs. Lyon: IARC Press 2004; p.54-5.
28. Sobin LH, Gospodarowicz MK, Wittekind C. UICC TNM Classification of Malignant Tumours. 7th ed. Wiley-Liss; New York NY: 2009.
29. United Nations Scientific Committee on the E ffects of Atomic Radiation (UNCERAR), "Sources and e ffect of ionizing radiation," UNSCEAR 2000 Reports to the General Assembly, with Scientific Annexes, New York, United Nations, 2000.
30. S. Acharya, K. Sarafoglou, M. LaQuaglia et al., "Thyroid neoplasms after therapeutic radiation for malignancies during childhood or adolescence," Cancer, vol. 97, no. 10, pp. 2397–2403, 2003.
31. Patricia Papendieck, Laura Gru~neiro-Papendieck, et al. Differentiated Thyroid Cancer in Children: Prevalence and Predictors in a Large Cohort with Thyroid Nodules Followed Prospectively- J Pediatr 2015;167:199-201.
32. Ortiz Sebastian S, Rodriguez Gonazles JM, Parilla Paricio P, et al. Papillary thyroid carcinoma: prognostic index for survival including the histological variety. Arch Surg 2000; (135):272–277.
33. Fridman MV, Man'kovskaia SV, Kras'ko OV, Demidchik IuE. Comparative clinical and morphological analysis of technogenic and cryptogenic papillary thyroid carcinoma in children and adolescents. Arkh Patol. 2014;76(5):20-5.
34. Kim HJ, Sohn SY, Jang HW, Kim SW, Chung JH. Multifocality, but not bilaterality, is a predictor of disease recurrence/persistence of papillary thyroid carcinoma. World J Surg. 2013;37:376–384.

Correspondence to:
Căpraru Oana-Maria
Department of Endocrinology,
Emergency County Hospital, Tîrgu-Mureș,
Gheorghe Marinescu Street, 50,
Romania
E-mail: oanacapraru@yahoo.com

CHARACTERISTICS OF PEDIATRIC TUBERCULOSIS IN A HIGH ENDEMIC AREA

Elena Danteş[1,2], Ariadna Petronela Fildan[1,2], Adriana Socaci[3], Raluca Railanu[2], Emanuel Tudorache[3,4], Cristian Oancea[3,4]

Abstract

Introduction: Tuberculosis (TB) is an important cause of morbidity and mortality in children, especially in high endemic regions as Romania. Pediatric TB reflects both the epidemic level of the region and the control measures efficiency of national programs in the territory. Supporting the diagnosis of TB in children is more difficult than in adults, because the bacteriological test for Mycobacterium tuberculosis is usually negative.

Objective: observe the clinical, bacteriological and radiological profile of tuberculosis in children and adolescents, including difficulties in diagnosis, monitoring and treatment.

Methods: the data were collected from patients' files from 1st January 2014 until 1stNovember 2015, for all the children and adolescents under the age of 18, diagnosed with pulmonary TB in the Pediatric Department of Clinic Pneumophysiology Hospital Constanta, Romania. We reviewed the patient files and noted a number of variables which included: age, sex, family history, patient's history, signs and symptoms, bacteriological examination (smear and culture), tuberculin skin test, TB exposure, smoking habits, lesions on chest x-ray, treatment and evolution.

Results: During the 22 months, 101(13,5%) patients out of the 748 patients treated in the pediatric pulmonology department were diagnosed with TB. The gender distribution was uniform: 53 (52,5%) female and 48 (47,5%) male. The frequency of TB cases increased with age: 3 (3%) cases under 5 years old, 26 (25,7%) between 5 and 9 years old, 31(30,6%) between 10-14 years old and 41(40,5%) cases between 15 and 18 years old. Most patients were symptomatic (87%), the most frequent symptoms reported were: fever (65%), cough (74%), decreased appetite (70%) and decreased weight (65%). A close contact with a contagious secondary TB disease was found in 50 patients (49,5%). The tuberculin skin test (TST) was positive in 82 patients (81%). We found 47 patients with benign form of primary TB, 4 primo-secondary TB (post-primary TB), 26 secondary TB and 24 pleural TB effusions. 23 patients had smear-positive and positive culture. The chest X-ray included adenopathy (+- elements of the Gohn Complex), nodules, infiltrate or parenchymal cavity.

Conclusions: In our study, the largest share of TB cases was met in the age group: 15-18 years. Most patients reported the presence of suggestive classic symptoms of tuberculosis. There were differences between the two groups of children and adolescents, in relation to diagnostic criteria role in supporting the diagnosis of certainty or diagnosis of probability. The benign primary TB was the most frequent form, being present in all age groups, in a significantly higher proportion of cases compared to primo-secondary, secondary and pleural forms. Pleural effusion was present in one third of the TB cases occurred between 15-18 years old, in 31,7% of cases. Culture-confirmed cases were more common in the group of adolescents. The diagnosis of TB disease in children remain a challenge for the pulmonologist based on the fact that bacteriological confirmation is rarely achieved.

Key words: pediatric tuberculosis, TB contact, primary TB, adenopathy, tuberculin skin test, cavitary TB

Introduction

Tuberculosis (TB) is an important cause of morbidity and mortality in children, especially in high endemic regions as Romania. Pediatric Tuberculosis reflects both the epidemic level of the region and the control measures efficiency of national programs in the territory[1-4]. Worldwide, there were reported 1 million new TB cases in children in 2014, and 140000 deaths[5]. Pulmonary TB is a contagious infectious disease caused by Mycobacterium tuberculosis (M. tuberculosis)[1]. The source is the infectious index TB patient who spreads bacilli during coughing, sneezing, talking, singing[6,7]. Children who are exposed to a contagious case can get infected, but only 5-10 % of them get active TB disease during their life[6,8].

In Romania, the global incidence of TB being high (70%000 inhabitants), TB infection occurs during childhood, compared to low endemic countries where age moves towards young adult.

[1]"Ovidius" University, Faculty of Medicine, Constanta
[2]Clinical Pneumophtysiology Hospital of Constanta
[3]"Victor Babes" Clinical Hospital of Infectious Diseases and Pneumology, Timisoara
[4]"Victor Babes" University of Medicine and Pharmacy, Timisoara
E-mail: elena.dantes@gmail.com, ariadnapetrofildan@yahoo.com, adriana_socaci@yahoo.com, raileanu_raluca@yahoo.com, tudorache_emanuela@yahoo.com, oancea@umft.ro

TB infection is asymptomatic in many children (85% cases), they remaining healthy carriers of the TB bacillus. During childhood and adolescence the risk of developing active TB disease is different, the most exposed being those under 5 years old and the HIV infected[7]. Generally, for children under 2 years old, infection progress to disease the in first year after infection[8].

Prolonged household contact, malnutrition, immune debilitating diseases, particularly HIV infection, genetic factors and virulence of the bacillus are high risk TB factors, that favour progression infection to active disease [1,8,9]. The diagnosis of TB disease in children is often difficult and it is based on epidemiological criteria, positive tuberculin skin test, suggestive sign of TB on chest radiograph, bacteriological exam for M tuberculosis or histopathologic examination[8].

The clinical examination is nonspecific and the bacteriological confirmation is rarely achieved[1,3,8]. In the absence of the gold standard diagnostic criteria (bacteriology or histopathology), the decision to establish the diagnosis and specific antituberculosis treatment depends on clinician's experience, in most cases being a diagnosis of exclusion.

Objective

The present study aims to determine child tuberculosis particularities depending on age period and the most important changes of the disease in adolescents. Since this is the only hospital in Constanta county where pediatric TB is diagnosezed and treated, we consider that the study cohort is representative to characterize the features of this disease.

Material and Methods

The data were collected from patient's files from 1st January 2014 to 1st November 2015 from children and adolescents under the age of 18, diagnosed with tuberculosis in the Pediatric Department of Clinical Pneumophysiology Hospital Constanta, Romania. We reviewed the patient files and noted a number of variables which included: age, sex, family and patient's history, signs and symptoms (fever, cough, decreased weight and appetite), bacteriological examination (smear and culture), TST, TB exposure, smoking habits, chest X-Ray, treatment and evolution. We defined as Group 1 patients aged 0-4 years (infants and newborns included), Group 2 - preschool and school children aged 5-9 years, group 3 - school children between 10 and 14 years old (puberty included) and group 4 - adolescents aged between 15 and 18 years, considering that there are differences in terms of hormonal and immune status, as well as particularities in terms of exposure to infectious agents and different risk of developing TB.

Subsequently tuberculosis characteristics were compared between the group of children and the adolescents', invoking the threshold of 15, according to the notification data used by WHO and guidance TB report[5,10]. The children performed TST through Mantoux method using 5 tuberculin units (TU) of M. tuberculosis PPD RT 23 (Statens Serum Institut, Copenhagen, Denmark). After 72 hours the transverse diameter of induration was measured. We considered a positive TST with an induration higher or equal to 10 mm in diameter (all being immuno-competent and BCG vaccinated children). A close contact was considered when the child had been exposed to a recent contagious TB case (sputum smear-positive).

A standard antero-posterior (AP) followed by a lateral chest X-Ray was done for all cases. Those with suggestive radiological signs of TB were subjected to bacteriological examination of sputum or gastric aspirate. In the presence of pleural effusion we perform thoracentesis with biochemical and cytological examination of pleural fluid. In order to sustain TB etiology we considered a value of adenosine deaminase (ADA) more than 40 UI associated to lymphocytic exudative effusion being strong criteria for high probability of TB diagnosis and start anti-TB treatment.

Statistical analysis of the data was carried out using the Graph Pad Prism software. The statistical significance of tests performed was interpreted according to *p* value. The frequencies of symptoms, radiological signs, results in TST and bacteriological confirmation were compared between the age groups.

Results

From January 2014 until October 2015, 101 children and adolescences aged between 0 and 18 years (13,5% out of the 748 patients) were diagnosed with TB and treated in the pediatric pulmonology department. The gender distribution was uniform: 53 (52,5%) female and 48 (47,5%) male. Frequency of TB cases increasing with age: 3 (3%) cases under 5 years old, 26 (25,7%) between 5 and 9 years old, 31 (30,6%) between 10-14 years old and 41(40,5%) between 15 and 18 years old. 47 (46,5%) patients were diagnosed with primary TB, 4 (4%)patients ere diagnosed with primo-secondary TB, 24 (23,7%) patients with pleural effusion and 26 (25,7 %) patients with secondary TB (fig. 1). The benign primary TB was the most frequent form, being present in all age groups, in a significantly higher proportion of cases compared to primo-secondary, secondary and pleural forms ($p<0.05$). Primo-secondary forms in patients over 10 years old were present in 4% of the cases, being more rare than other forms of TB ($p<0.001$).

The incidence of primary TB forms was significantly higher in the age groups 5-9 years (44,70%) and 10-14 years (36,19%), compared to groups under 5 and those between 15-18 years old ($p<0.05$), and secondary TB forms were more frequent (76%) in the age group 15-18 years ($p<0.05$), and being absent in children under 10 years old. Pleural effusion was present in one third of the TB cases occurred between 15-18 years old, in 31,7% of cases, and in 15,3% of TB cases in children of 5-9 years old ($p<0.001$) (figure 1).

Most patients were symptomatic, the most frequent symptoms being fever (65%), cough (74%), decreased appetite (70%) and weight loss (65%). A close contact with an active secondary TB disease was found in 50 patients (49,5%). The tuberculin skin test was positive in 82 patients (81%) (table 1).

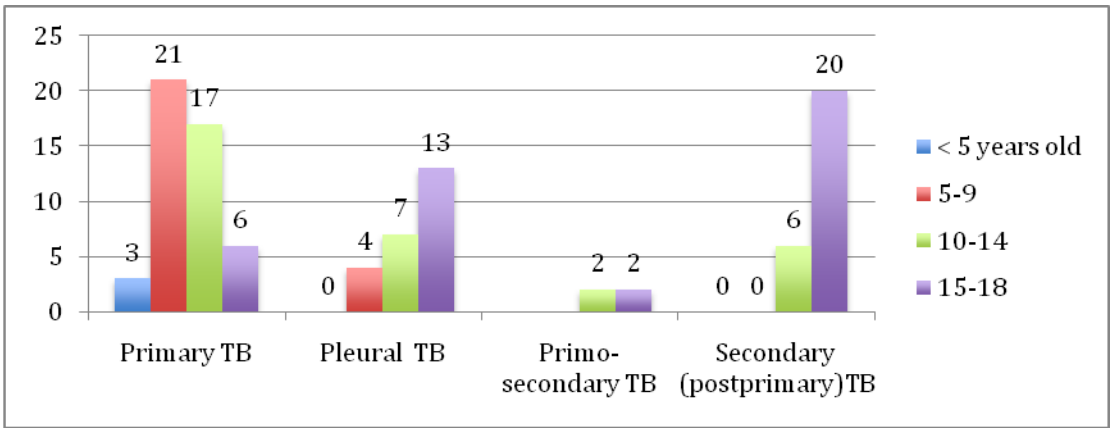

Figure 1. Distribution of TB forms by age group.

Table 1. Chacterisitics of TB forms: primary, primo-secondary, secondary and pleural TB.

N= (%)	**Primary TB n=47; (46,5)**	**Pleural effusion n=24 (23,7)**	**Primo-Secondary TB n =4 (3,9)**	**Secondary TB n=26 (25,7)**
Female	20 (46)	10 (41)	2 (50)	16 (61)
Male	27 (57)	14 (58)	2 (50)	10 (38)
BCG	47 (100)	23 (95)	4 (100)	26 (100)
Age:				
Under 5,	3 (6)	0		0
5-9,	21 (44)	4 (16)		0
10-14,	17 (36)	7 (29)	2	6 (23)
15-18.	6 (12)	13 (54)	2	20 (84)
Close TB contact	30 (63.8)	5 (20.8)	3 (75)	11 (42.3)
Smoker/ nonsmoker/UN	2/41/5 (4.2/87.2/10)	8/15/1 33.3/62.5/4,1)	1/3 (25/75)	7/11/8 (27/42.3/30)
Fever	25 (53)	19 (79)	3	19 (73)
Cough	27 (57)	22 (91)	3	23 (88)
Loss weight	25 (53)	20 (83)	4	17 (65)
Loss appetite	23 (48)	21 (87)	4	23 (88)
TST positive	44 (93.6)	20 (83.3)	3 (75)	15 (57.7)
TST negative	3 (6.3)	3 (12.5)		2 (7.7)
TST UN		1		10 (37)
Chest X-Ray				
Adenopathia (+_ other elements of the Gohn Complex)	47 (100)	1	4	0
Nodule	4 (8.5)	0	2 (50)	15 (57)
Parenchymal cavity	0	0	3 (75)	14 (53)
Infiltrate	1 (2.1)	0	2 (50)	13 (50)
M tuberculosis				
baar +	1 (2,1)	0		17(65.3)
Culture positive	1 (2,1)	4		13 (50)

BCG: bacilli Camette Guerin, UN- unknown

Distribution TB forms by sex was uniform, with no significant statistical differences (p>0.05) (table 1). Primary and primo-secondary forms reported TB contact in a higher proportion of cases compared to secondary TB forms, but without statistical significance, statistically significant differences being observed in those cases with pleural involvement (p<0.05).

Symptoms and TST positive were present in equal proportions in all forms of TB, noting that in secondary forms, TST test was not performed in a third of cases (in smear-positive cases). Hilar adenopathy was the radiological feature regularly present in primary and primo-secondary forms, whereas nodules, cavity and infiltrate were found in approximately equal proportions in secondary forms of TB. These radiological aspects were correlated with bacteriological examination, most confirmations being encountered in secondary forms, over 65% positive cases after the direct microscopic examination.Tuberculosis in children was more common among girls (53.3%), and in adolescents, among boys (51.2%).

Regarding the smoking habit, it was more commonly encountered in primo-secondary, secondary and pleural forms, compared to the group of patients presenting primary forms (p<0.05). No smoker was reported in children with TB, whereas this habit was present in 44% cases in adolescents.

Symptoms and TST were observed with approximately equal frequency in children and adolescents. Adenopathies were significantly more common in children (p=0.01), whereas nodular forms, cavities and infiltrations were more frequent in adolescents (p=0.01) (figure 2).

Culture-confirmed cases were statistically significantly more in the group of adolescents (34.7% vs. 8.3%, p=0.01), and the smear-positive were more common in this age group, but without statistical significance (table 2). Pleural effusions were observed in approximately equal proportions in the two age groups, with an ADA value of over 64 U/l in both groups of patients.

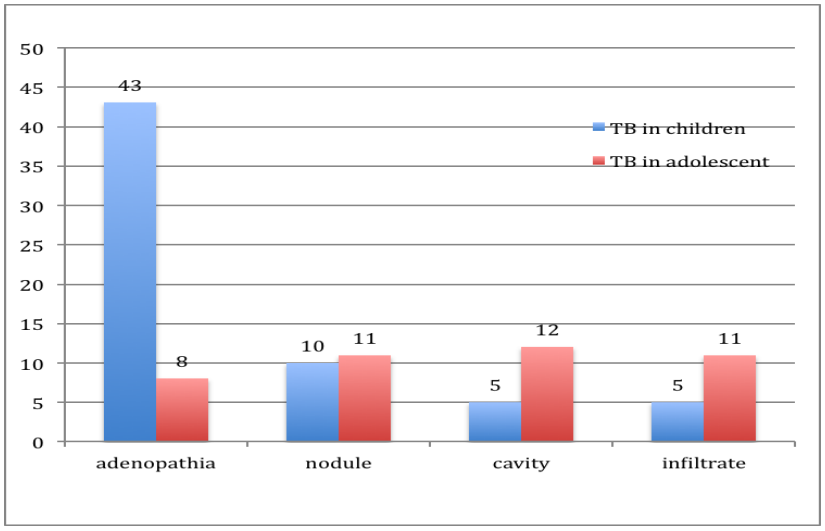

Figure 2. Distribution of radiological forms in children cohort and adolescent cohort.

Table 2. Characteristics of TB in child compared to TB in adolescent.

TB patients n=, (%)	Male	TB contact	Smokers	Sympt.	TST +	smear +	M. tuberculosis Culture +	Pleural effusion	ADA (U/l)
Children n=60 (59,4)	28 (46,7)	32 (53.3)	0	36 (87)	54 (90)	10 (16,6)	5 (8,3)	11 (18.3)	64,58
Adolescents n=41(40,6)	21 (51)	18 (43.9)	18 (44)	52 (86)	28 (68)	14 (34)	13 (31,7)	13 (31.7)	64,09
p value	ns	ns	p<0.05	ns	ns	Ns	p=0.01	ns	ns

Discussion

The study pursued the clinical, imaging, bacteriological and immunological (TST) characteristics of tuberculosis forms present in children, compared to those observed in adolescents. All cases diagnosed in the Department of Pediatric Pneumology during the period 1st of January 2014 until 1st of November 2015 were evaluated. The Department is unique in Constanta and Tulcea counties, reason for which we consider the cohort characteristic for Dobrogea region. The TB surveillance in Constanta County highlights incresed values of global incidence 80%000 in 2014 and global incidence in children (0-14 years old) 34%000, Constanta being in the first 5 counties with the highest incidence in Romania. In 2014, 38 new cases were registered in the National Unique TB Registry and by 1st of November 2015, another 37 new TB cases in the population aged 0-15 years. In the present study, assessment of tuberculosis cases showed that TB frequency has increased with age, a small number of cases were found in patients aged under 5, and this period of time is known in literature as the period with the highest risk for tuberculosis [1,7].

Distribution of patients by sex was uniform, both in children and in adolescents (46%: 54% respectively 51%:49 %), different from the data at national level, which show a male : female ratio of 2:1[11]. The percentage of TB cases for which the source had been identified, was higher than in other studies (53,3% vs. 43,9% in the children cohort vs. adolescent cohort, totally different from 27,8% in Marais' study)[2]. In children, a close contact with family members is more frequently identified. Smoking as a TB risk factor in children is debatable, but the present study showed the fact that 44% of adolescents were smokers when they were TB diagnosed. This result may be considered an alarm regarding the early age they started smoking, that bronchial mucosal is exposed to substances that alter the ability of local defense, the so-called cell-mediated immune response, against M. tuberculosis infections. Symptoms were present in most patients (87%).

The most common symptoms include fever (over 60%), chronic cough for more than 3 weeks (over 70%), weight loss (over 63%), loss of appetite (over 65%). No significant differences in symptom prevalence existed between age groups (0-15 years old, 15-18 years old). The results are similar to those in other studies. For example, Marais' study that followed the prevalence of symptoms associated with pulmonary tuberculosis in children from a high burden community showed the constant presence of a combination of symptoms traditionally associated with tuberculosis, but have limited diagnostic value.

Weight loss and coughing have a positive predictive value of 5%[2]. WHO reports a frequency of 0.6%–3.6% of smear-positive in children under 14 years old and 95% negative smear in children under 12 years old[7]. In our study we found 16.6% cases of smear-positive, in more severe TB cases. Other studies report less than 15% acid fast bacilli smear-positive and 30-40% confirmation in culture[7,12,13].

It is difficult to obtain a sample of good quality sputum in children and for this reason induced sputum method is recommended[14,15]. Positive TST supports the diagnosis of infection and it should be interpreted with caution as a diagnostic criterion in BCG vaccinated population or in the endemic areas. In younger age groups, it is required differentiation of post-vaccination immunity given by BCG by performing Quantiferon test. Intrathoracic adenopathies and lung lesions were present on chest-X-Ray up to 80% of the child's TB[16]. As literature showed, hilar enlarged lymph node was the most frequent modification observed in our patients (78% under 15 years of age). 11 children presented pleural effusion (26%).

The TB diagnosis was confirmed by positive culture but this appears in extensive forms like cavity specific in adolescent TB. In the negative smear and culture forms of TB, guidancelines recommend other criteria for diagnosis: household contact, complex of symptoms, chest X-Ray, TST and excluding other causes of illness. In high endemic countries contact may be extended extra-domiciliary[17]. Computed tomography of chest was not routinely used to confirm the presence of adenopathies given the risk of radiation at that age. Fiberbrochoscopy was performed in 7 cases of extrinsic compression suspicion and it was confirm in 6 cases. Ganglio-bronchial fistula was present in one case. Pleural effusion was the main TB form of presentation in the adolescents` cohort (31.7 % vs18%). 4 cases (20%) of pleural effusion were confirmed by positive M. tuberculosis culture in pleural fluid, and the mean value ADA was 64 UI in both cohorts, similar with literature data[18]. Pleural biopsy was not possible in the department.

The study had several limitations. It is estimated that diagnosis for child tuberculosis is one of exclusion. Correct diagnosis by positive culture was established only in 21 cases (20.7%), 15 being from adolescents' group. In this case, as in the others, presented above, the data are consistent with those in specialized literature. Clinical, epidemiological, TST and radiological criteria remain key elements for high probability diagnosis sustained by the specialist.

Conclusions

In our study, the largest share of TB cases was met in the age group: 15-18 years. Most patients reported the presence of suggestive classic symptoms of tuberculosis. There were differences between the two groups of children and adolescents in relation to diagnostic criteria role in supporting the diagnosis of certainty or diagnosis of probability. The benign primary TB was the most frequent form, being present in all age groups, in a significantly higher proportion of cases compared to primo-secondary, secondary and pleural forms. Pleural effusion was present in one third of the TB cases occurred between 15-18 years old, in 31,7% of cases. Culture-confirmed cases were more common in the group of adolescents. The diagnosis of TB disease in children remains a challenge for the pulmonologist based on the fact that bacteriological confirmation is rarely achieved.

References

1. Nelson LJ, Wells CD. Global epidemiology of childhood tuberculosis. Int J Tuberc Lung Dis 2004;8:636–647.
2. Marais BJ, Obihara CC, Gie PR, et all.The prevalence of symptoms associated with pulmonary tuberculosis in randomly selected children from a high burden community. Arch Dis Child 2005; 90:1166–1170. doi: 10.1136/adc.2004.060640
3. Donald PR. Childhood tuberculosis: out of control? Curr Opin Pulm Med 2002;8:178–82.
4. Walls T, Shingadia D. Global epidemiology of paediatric tuberculosis. J Infect 2004;48:13–22.
5. http://www.who.int/tb/publications/global_report/2015/en/index.html. 2015
6. Batra V. Pediatric tuberculosis. UpToDate
7. Swaminathan S, Rekha B. Pediatric Tuberculosis: Global Overview and Challenges. Clinical Infectious Diseases 2010;50(S3):S184–S194
8. Marais BJ, Gie RP, Schaaf HS, et al. The natural history of childhood intra-thoracic tuberculosis: a critical review of literature from the pre- chemotherapy era. Int J Tuberc Lung Dis 2004; 8:392–402.
9. http://www.who.int/tb/publications/en/index.html. Accessed 24 March 2010.
10. Enarson D A, Rieder H L, Arnadottir T, Trebucq A. Management of tuberculosis. A guide for low income countries. Fifth edition. Paris, France: International Union Against Tuberculosis and Lung Disease, 2000
11. http://www.ms.ro/documente/GHID%20Metodologic%20 PNPSCT %20FINAL%20-17.06.2015 (aprobat%20Comisie%20Pneumo)%20ultima%20varianta_1124_2279.pdf
12. Cruz AT, Starke JR. Clinical manifestations of TB in children. Pediatr Respir Rev 2007;8:107–117.
13. Eamranond P, Jaramaillo E. Tuberculosis in children: reassessing the need for improved diagnosis in global control strategies. Int J Tuberc Lung Dis 2001;5:594–603.
14. Marais BJ, Pai M. New approaches and emerging technologies in the diagnosis of childhood tuberculosis. Pediatr Respir Rev 2007;8: 124–133.
15. Swaminathan S, Datta M, Radhamani MP, et al. A profile of bacteriologically confirmed: pulmonary tuberculosis in children. Indian Pe- diatr 2008;45:743–747.
16. Starke JR. Tuberculosis. In: Jensen HB, Baltimore RS, eds. Pediatric infectious diseases: principles and practices. Philadelphia: WB Saun- ders, 2002:396–419.
17. Marais BJ, Pai M. Recent advances in the diagnosis of childhood tu-berculosis. Arch Dis Child 2007;92:446–452
18. Reechaipichitkul W, Kawamatawong T, Teerajetgul Y, Patjanasoontorn B. Diagnostic role of pleural fluid adenosine deaminase in tuberculous pleural effusion.Southeast Asian J Trop Med Public Health. 2001 Jun;32(2):383-9.

Correspondence to:

Ariadna Petronela Fildan
M8 street, no.12,
905700,
Navodari, Constanta
Phone: +40741157526
E-mail: ariadnapetrofildan@yahoo.com

AORTIC COARCTATION IN INFANTS AND CHILDREN – DIAGNOSE, TREATMENT AND PROGNOSIS

Gabriela Doroş[1,2], Anca Popoiu[1,2], Cristina Olariu[2], Alexandra Popescu[2], Ramona Olteanu[2], Raluca Isac[2], Mihai Gafencu[1,2]

Abstract

Coarctation of the aorta is a congenital heart defect involving a narrowing of the descending aorta. Blood pressure is higher before the narrowing and lower past the narrowing, with 20 mmHg difference between upper and lower limbs, clinically expressed by absent femoral pulses. In infants, coarctation of the aorta is severe and represent a cardiological emergency, but in child, aortic coarctation is sometime under-diagnosed, patients presenting at the hospital for high blood pressure of unknown etiology, or complaining of headache, or lower limb pain in effort.

We want to highlight aortic coarctation as a cause of high blood pressure in children and to drawn attention that this kind of patients, even after aortic coarctation repair may remain with hypertension that has to be treated and patients followed up. We want to share our experience with some cases of surgical correction of aortic coarctation and complications such as recoarctation in special type of gothic aortic arch and also, recoarctation after stent implanting.

Key words: coarctation of the aorta, high blood pressure, children, infants, recoarctation

Introduction

Coarctation of the aorta (CoAo) or descending aorta narrowing is a relatively common defect that accounts 5-8% of all congenital heart defects, with a prevalence of 4 in 10 000 live birth. Coarctation of the aorta may occur at any point after the transverse arch, to the iliac bifurcation, but 98% occur just below the origin of the left subclavian artery at the origin of the ductus arteriosus (juxtaductal coarctation - Fig. 1); rarely, a coarcted segment is present in the lower thoracic or abdominal aorta. It may be as an isolated defect or in association with various other lesions, most commonly bicuspid aortic valve (may be seen in nearly two thirds of infants with coarctation of the aorta), hypoplasia of the aorta, ventricular septal defect, atrial septal defect, transposition of great arteries, and patent ductus arteriosus and complex lesions. Boys have the defect more commonly than girls and the ratio is 2:1, excepted Turner syndrome.

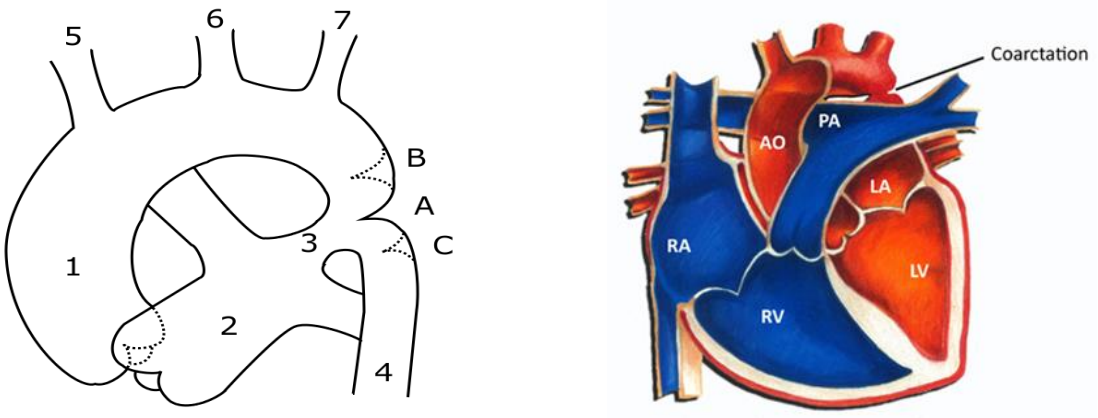

Fig 1. a. Schematic drawing of alternative locations of a coarctation of the aorta, in relation to the ductus arteriosus. A: Ductal coarctation, B: Preductal coarctation, C: Postductal coarctation. 1: Ascending aorta, 2: Pulmonary artery, 3: Ductus arteriosus, 4: Descending aorta, 5: Brachio-cephalic Trunk, 6: Common left carotid artery, 7: Left subclavian artery.; b. Coarctation of the aorta.

[1]"Victor Babeş" University of Medicine and Pharmacy Timişoara, Romania
[2]"Louis Turcanu" Children's Emergency Hospital Timişoara, III[rd]Pediatric Clinic
E-mail: gdoros@gmail.com, apopoiu@umft.ro, olariu.ioanacristina@yahoo.com, popescu.mariaalexandra@yahoo.com, ramona_veronica_tudor@yahoo.com, ralu_isac@yahoo.com, mgafencu@umft.ro

Clinical presentation and examination

In *fetal life*, coarctation of the aorta can be diagnosed by fetal echo, but with no severe consequences on fetus, because of the ductus arteriosus circulation.

After birth, some of the newborns with aortic coarctation will remain asymptomatic due to a good antegard aortic flow through the aortic isthmus and normal ductal flow, but about half of *newborns* with coarctation of the aorta will develop symptoms in the first days/weeks of life, after ductal closure. This neonates start to have hemodynamic deterioration, with poor feeding, poor weight gain, dyspnea, cyanosis in the lower part of the body, because the circulation in the lower part of the body is through the ductus arteriosus, right to left and soon after, in the time of ductal cosure, they start to develop tachypnea, tachycardia, and cardiogenic shock, because of hypoperfusion of the abdominal organs, leading to severe metabolic acidosis and kidney failure. The diagnose include blood pressure (BP) discrepancies between the extremities, with high blood pressure in the upper part of the body and minimum 20 mmHg lower pressure in the lower part of the body and reduced or absent pulses at the femoral artery. Echocardiography will confirm the aortic coarctation. Neonates in this condition need urgent treatment for heart failure with short-acting inotropic agents, correction of acidosis, sometime intubation and mechanical ventilation before immediate surgical correction.

In *children*, aortic coarctation is generally asymptomatic and is incidental discovered and diagnosed. Children are sometime complaining of headache, leg pain after effort, claudication, epistaxis. At the clinical examination, they can be discovered with cardiac murmur and high blood pressure in the arms and absent or diminished femoral pulse. In coarctation of the aorta, blood pressure is higher before the narrowing of the aorta and lower past the narrowing, with a minimum 20 mmHg difference between upper and lower limbs, associated with absent femoral pulses. Symptoms depend on how much blood can flow in the lower part of the body, through the coarctation. During time, collateral circulation from aorta will develop in the upper part of the body, to feed the lower part of the body.

In milder cases, symptoms may not develop until the child has reached adolescence. Other symptoms include: chest pain, cold feet or legs, dizziness or fainting, decreased ability to exercise, failure to thrive, leg cramps with exercise, nosebleed, poor growth, pounding headache, shortness of breath.

Diagnose

It is based on clinical examination, electrocardiography (ECG), cardiopulmonary X-ray, echocardiography, angioCT with 3D reconstruction or angio MRI and if necessary catheterization.

Electrocardiography in newborn will show right axis deviation and right ventricular hypertrophy, much frequent than left ventricular hypertrophy; in children, ECG may be normal in 20% of cases, meaning large coarctation, or may reveal left ventricular hypertrophy, meaning narrow coarctation.

Cardiopulmonary X-ray will show marked cardiomegaly with pulmonary edema or pulmonary venous congestion in newborns and on barium esophagogram the "E" shaped indentation or reversed figure of "3"sign configuration and rib notching in children older than 5 yo, due to collateral circulation.

Echocardiography, from suprasternal notch will show the location of the coarctation and with continuous Doppler will measure the gradient through the coarctation.

Angio CT with 3D reconstruction is the investigation that reveal the exact site and the size of the coarctation and the collateral circulation. The time for this investigation is very short and applicable in newborn and infants, but this method is irradiating.

Angio MRI is also a perfect investigation to reveal the aortic coarctation, non-irradiating, but with long time of sedation. It is perfect for older children, that cooperate and do not need sedation, or for small children that do not cooperate and need sedation.

Catheterisation is not a diagnostic tool now, but it is used in the treatment of aortic coarctation, a perfect method for interventional dilatation and stent implantation.

Treatment

Medical treatment

In symptomatic newborns, prostaglangin E1 has to be started to reopen the duct, to assure good blood flow to the kidney. In case of heart failure, short-acting inotropic agents as dopamine or dobutamine, diuretics and oxygen is needed before surgery.

Systemic hypertension has to be treated with beta blockers in older children. Lifelong prophylaxis of bacterial endocarditis is necessary in case of bicuspid aortic valve.

Surgical treatment

Surgical repair can be done by four techniques: resection of the coarctation and end to end anastomosis of the aorta, enlarging the coarcted zone by parching with Dacron, or subclavian flap repair, or conduit insertion in place of aortic coarctation if this is expressed on a large segment of the descending aorta, all done by left lateral thoracotomy. All four techniques have a high rate of recoarctation, especially if the correction is in newborn period or infants. The intervention by parching with Dacron is no longer used, because of a high rate of aneurysm formation. The flap repair needs the left subclavian artery to be legated because the proximal part is used to patch the coarcted segment and the patient is pulsless in the left arm, where the circulation will be assured by collaterals. If the symptomatic newborns are not operated, the mortality rate is around 90%.

Interventional treatment

Interventional balloon dilatation was introduced to treat recoarctation after surgery intervention, but soon after became the first option in the treatment of aortic coarctation in children. Rare complications can be mentioned as: aortic dissection, rupture and aneurysm formation. The age for

balloon dilatation depends on the center to center experience, but still remain the risk for recoarctation

Interventional stent implantation became the treatment of choice in aortic coarctation, with low rates of immediate complications. Despite these, recognized complications are: aneurysm formation, stent fractures and recoarctation, with a lower rate comparing with surgery. Reintervention and stent in stent implantation is possible. Angio CT is used to detect de post procedural aneurysm formation and the stent integrity.

Follow-up and Prognosis

Even after early surgery or interventional repair of aortic coarctation, approximately 30% of patients will be hypertensive by adolescence. 60% of adults, after correction of aortic coarctation in childhood will be hypertensive. This is the reason this kind of patients have to be followed up at 6-12 months. A part of the patients have normal rest blood pressure, but at exercise develop exaggerate blood pressure response, meaning the onset of overt hypertension. In time has to be followed complications regarding the bicuspid aortic valve, aneurysm formation, stent recoarctation and persistent hypertension that have to be medicated. Prognosis depends on complications.

Our experience in follow up complications

We want to highlight two children with aortic coarctation, a girl and a boy, both surgical operated at the age of 5 with end to end anastomosis. They were followed up yearly. In time, they stared to develop recoarctation, with significant gradient, hypertension in the arms, headache and pain in the legs. Both were on medication for high blood pressure.

The first case, the girl, at the age of 10 performed angio CT with 3D reconstruction, confirming the recoarctation detected by echocardiography. She had an interventional stent implantation, with good result after implantation, becoming free of symptoms. This was the reason she didn't come for follow up evaluation during a 6 months period. After that time, high blood pressure and headache reappeared and she came for a cardiology check. Significant gradient was found at echocardiography and a new angio CT was done, confirming that the stent was not complete expanded. She performed a new interventional dilatation of the stent and the gradient dropped to normal. Despite this, high blood pressure persisted, and antihypertensive treatment was continued. She is now in a regular follow up program, but free of symptoms.

The second case, a 12 yo boy started to develop high blood pressure and he was medicated. In time he developed severe headache associated with high blood pressure, despite the medication. At echocardiography he presented serial stenosis due to a gothic aortic arch and associated bicuspid aortic valve with no gradient, but with a subaortic restrictive ventricular septal defect. The gradient was not severe at the level of the surgical operated aortic coarctation, but in serial stenosis, echocardiography is not perfect in detecting the gradient. An angio CT was performed, with 3D reconstruction, reflecting the stenotic areas of the aortic root, due to the gothic aortic arch and the recoarctation. He performed a catheter exploration and balloon dilatation, because stenting was impossible in his aortic arch, due to the risk of obstructing the left common carotid artery. After balloon dilatation he was free of symptoms, but still on medication for high blood pressure. He is in a regular 3 mo follow up program, and in case of symptoms correlated with high gradient, he will perform a complete surgical correction in an experienced cardiovascular surgery center.

Conclusion

Coarctation of the aorta or aortic narrowing is the fifth most common defect that accounts for 5-8% of all live births with congenital heart defects. Absent femoral pulse associated with high blood pressure in upper extremities can suspect this diagnose of aortic coarctation. Newborns and infants who present early with severe coarctation of the aorta are seriously ill and require urgent medication and transfer to a pediatric cardiovascular center for balloon dilatation or surgical corection. Postsurgery re-coarctation has to be followed. Interventional balloon dilatation and stent implantation or surgical correction in selected cases has to be performed in children. Even so, patients have to be followed up because of complications such as recoarctation or persistence of high blood pressure that has to be medicated.

References

1. Ali Devrim Karaosmanoglu, Ranish Dedar Ali Khawaja, Mehmet Ruhi Onur, Mannudeep Karla. CT and MRI of Aortic Coarctation: Pre- and Postsurgical Findings. American Journal of Roentgenology. 2015, Vol. 204, Issue 3
2. Yuan SM., Raanani E. Late complications of coarctation of the aorta. Cardiol J. 2008;15(6):517-24
3. Chakrabarti S., Kenny D., Morgan G., Curtis SL., Hamilton MC., Wilde P., Tometzki AJ., Turner MS., Martin RP. Balloon expandable stent implantation for native and recurrent coarctation of the aorta--prospective computed tomography assessment of stent integrity, aneurysm formation and stenosis relief. Heart. 2010;96(15):1212-6. Epub 2009 Sep 10.
4. Budoff MJ., Shittu A., Roy S. Use of cardiovascular computed tomography in the diagnosis and management of coarctation of the aorta. J Thorac Cardiovasc Surg. 2013;146(1):229-32. Epub 2013 Feb 8.
5. Malčić I., Kniewald H., Jelić A., Sarić D., Bartoniček D., Dilber D., Belina D., Anić D. Coarctation of the aorta in children in the 10-year epidemiological study: diagnostic and therapeutic consideration. Lijec Vjesn. 2015;137(1-2):9-17.

6. O'Brien P., Marshall AC. Coarctation of the aorta. Circulation. 2015;131(9):e363-5
7. Dzsinich C., Vaszily M., Vallus G., Dzsinich M., Berek P., Barta L., Darabos G., Nyiri G., Nagy G., Pataki T., Szentpétery L. Late complications and treatment options of aortic coarctation operated in childhood. Orv Hetil. 2014; 27;155(30):1189-95.
8. Harris KC, Du W, Cowley CG, Forbes TJ, Kim DW. A prospective observational multicenter study of balloon angioplasty for the treatment of native and recurrent coarctation of the aorta. Congenital Cardiac Intervention Study Consortium (CCISC). Catheter Cardiovasc Interv. 2014 ;1;83(7):1116-23. Epub 2013 Dec 4.

Correspondence to:
Gabriela Doroş
"Victor Babeş" University of Medicine
and Pharmacy Timişoara
Eftimie Murgu, 2,
Timişoara
Romania
E-mail: gdoros@gmail.com

CLINICAL ASPECTS IN EPSTEIN-BARR AND CYTOMEGALIC VIRUS CO-INFECTION IN CHILDREN

Simona Dumitra[1], Carmen Crișan[1], Luminița Pilat[1]

Abstract

Background - Cytomegalovirus (CMV) and Epstein–Barr virus (EBV) usually cause primary and latent infections during childhood. Thus, a co-infection with these viruses can also occur occasionally in children. However, its clinical impact has not been yet established, and may be underestimated.

Aim – The authors described 5 cases of Cytomegalovirus (CMV) and Epstein–Barr virus (EBV) co-infection in children, emphasizing the polymorphism of clinical manifestations.

Methods - Case report 1 is a 3 years old child with prolonged fever in the context of a good general condition. Case report 2 is a 18-month-old toddler with hepatocytolisis and mild jaundice. Case report 3 is a 5 years old child with acute tonsilitis and generalized adenomegaly. Case report 4 is a teenager with toxic appearance, prolonged high fevers, chills, fatigue, and malaise, myalgias, headache, and pain in the left upper quadrant, splenomegaly. Case 5 is a teenager with high fever, myalgias, headache, acute tonsilitis, hepatosplenomegaly, exudative pharyngitis and cervical lymphadenopathy, moderately elevated serum levels of aminotransferases. In all cases the serology was positive for EBV and CMV.

Conclusions - The authors noticed the atypical expression of the 2 viruses in young age and the presence of classical elements of mononucleosis in a wide range and severe expression in adolescents.

Key words: Epstein Barr and cytomegalic virus, clinical aspects, child

Introduction

Infectious mononucleosis (IM) is a clinical syndrome most common among adolescents and young adults. It is characterised by fever, pharyngitis, fatigue, lymphadenopathy and hepatosplenomegaly. This viral disease is caused mainly by the Epstein-Barr (EBV) virus and Cytomegalovirus (CMV). These viruses can lie dormant and could be reactivated under host imunosupression conditions or by stimulation by other germs. However, most of the time there is a multiple etiology of the disease. This involves associations between viruses, the most frequent being between the Epstein-Barr virus (EBV) and Cytomegalovirus (CMV).

The diagnostic of IM can be done using serological tests that look for specific antibodies associated with the viruses such as capsid antigen (VCA) antibodies- IgM ± capsid antigen (VCA)-IgG, nuclear antigen (EBNA)-IgG, of anti-CMV antibodies-IgM, anti-CMV antibodies-IgG.

The search for these antibodies is a means of defining infection status as shown below or for differential diagnostic as the mononucleosis syndrome can be caused by other pathogens.

The acute infection with EBV is indicated by the presence of capsid antigen (VCA) antibodies- IgM ± capsid antigen (VCA)-IgG and the chronic infection is defined by the presence of nuclear antigen (EBNA)-IgG.

The acute infection with CMV is indicated by the presence of anti-CMV antibodies-IgM and the chronic infection by the anti-CMV antibodies-IgG.

The co-infection involves association of capside antigen (VCA-IgM) ± capside antigen (VCA-IgG) + anti CMV-IgM (1,2,3). This double infection can occur simultaneously or after a short time interval (IgM persist between 1 week and 3 months).

There is a possibility to reactivate these dormant viruses → EBV determine a decrease of the immunity with the decrease of the CD_4/CD_8 ratio and the possibility of expressing the latent infection with CMV (3,5,6).

Although is is considered that the infections with CMV and EBV are more frequent in adolescents, it seems that the primary infection occurs at a younger age, the expresion of the mononucleosic syndrome being more attenuated (4,7,9).

Beside IM, EBV is also involved in the Kawasaki disease, anaphylactoid purpura, imune trombocytopenic pupura, juvenile rheumatoid arthritis.

The clinical manifestations of IM include: high or prolonged fever, pharyngitis, lymphadenopathy, hard palate petechiae, rash, hepatosplenomegaly.

[1]„Vasile Goldis” Western University of Arad
E-mail: dumitrasimona@yahoo.com, carmencrisan73@yahoo.com, luminita.pilat@yahoo.com

The aim of this work

The aim of the present study is to outline the main clinical elements of the EBV + CMV co-infection in children.

Materials and method

Description of the clinical particularities in 5 children aged between 1 year and 8 months and 17 years diagnosed in the specialized ambulatory with a CMV – EBV co-infection (positive VCA-IgM, positive CMV-IgM and negative EBNA – IgG).

CASE 1

NA, 3 years old male, having for 10 days persistent fever with spikes at fixed hours (9^{00}, 18^{00}) amid an unchanged general state. Ten days after the first spike in fever, at the physical examination, an intensely congested larinx is noted with pultaceous deposits, lateral cervical adenopathy, without complaints.

The atypical picture, prolonged evolution, the erithemato-pultaceous aspect of the angina at this young age and the generaly good state has raised the suspicion of a IM.

Biologically, leukocytosis and monocytosis were detected and, the double infection with EBV and CMV was confirmed serologically.

CASE 2

CN, 1 year and 6 months old male, 6 days from the onset with fever with loss of appetite

Clinical aspect: discrete subicteric sclera

Biology: hepatic cytolysis (230 – 200 U/l), slightly increased direct bilirubin

The expanded range of investigations for the hepatic ailment detected the presence of positive IgM for CMV and EBV.

CASE 3

MA, 5 years old male, showing for 3 days high fever, dysphagia and adeno pharyngitis

Clinical aspect: enlarged tonsils, pseudomembranous deposits, lateral cervical adenopathy with swollen lymph nodes that are partially aderent, mobile and sensitive without signs of acute inflammation and with a proconsular neck aspect.

Biology: leukocytosis, lymphomonocytosis

Serology: confirmation of the co-infection

CASE 4

CA, 17 years old male.

Onset 2-3 days with high fever, affected general state, pain, marked fatigue, myalgia, headache, and left upper quadrant pain.

Clinical aspect: adenopathy, splenomegaly (explaining the constant left upper quadrant pain).

Stage diagnostic: food poisoning, flu

Abdominal echography: hepatosplenomegaly

Biology: leukocytosis, lymphomonocytosis, IgM CMV + EB, discrete hepatic cytolysis 200 UI/l.

CASE 5

RA, 15 years old female

Shows for 5 days high fever, headache, dysphagia

Clinical aspect: tonsils with pseudomembranous deposits, hepatospleomegaly, lateral cervical adenopathy

Biology: mononucleosic syndrome – etiology confirmed by positive IgM for EBV and CMV.

Results and discussion

The clinical expressions of each individual case are shown in Table 1.

Table 1. Mononucleosic syndrome – main characteristics.

Main characteristics	Case 1	Case 2	Case 3	Case 4	Case 5
General state	good	good	moderately affected	affected	affected
Adenomegaly	+	-	+++ (proconsular neck)	-	++
Pharyngitis	+ erithemato-pultaceous	-	+ pseudo-membrane	pultaceous	+ pseudo-membrane
Hepatomegaly	-	+	-	+	+
Splenomegaly	-	-	-	+ Left upper quadrant pain	+
Rash	-	-	-	-	-
Jaundice	-	±	-	-	-
Fatigue	-	-	-	+	+
Myalgia	-	?	-	+	+
Headache	?	?	-	+	+
Leukocytosis	+	+	+	+	-
Limphomonocytosis	+	+	+	+	+
R. hepatic	-	+	-	+	+

It can be observed that as the child grows, the mononucleosic picture is more complex, including more elements.

In adolescents, the co-infection accentuates the IM picture that is expressed by fever, angina, adenohepatospenomegaly amid an affected state, sometimes with flu like symptoms (head ache, fatigue, myalgia).

At young ages, atypical or subtle forms are predominant (prolonged febrile syndrome, loss of appetite and well tolerated erithemato-pultaceous tonsilitis).

None of the above cases has shown a rash or eyelid edema that were previously reported in literature (3, 5, 6, 8, 9, 10).

Ito (2009) described 3 cases in 1-3 years old children with EBV and CMV co-infection with IM, acute hepatitis and hemophagocytic lymphohistiocytosis with extended evolution (7).

Wang (2009) in a study on 190 patients with IM has identified 7 subjects with EBV and CMV co-infection of which 6 were younger than 6 years. All presented the typical signs on IM (fever, pharyngitis limphadenopathy, petechiae). Furthermore, only four had also had hepatosplenomegaly and none of them had rashes (13).

These observations are overlaping with the ones from our study, on young children (fever, tonsilitis, good general state → as mode of expression).

Chan's study (2003) on 77 children with IM has shown a peak of the co-infection between 2-4 years expressed by fever, pharyngitis, limphadenopathy. The hepatic affections occur in older children.

Studies done by Zenda (2004) (14) and Bravender (2010) (1) confirm that in adolescents the picture respects the clinical elements, also associating the hepatosplenomegaly, liver cirrhosis elements, headaches and myalgias. These observations are similar with the observations made on the adolescents from the present study.

According to Olson D., and Huntington MK. (2009) the latent infection with EBV is reactivated by the CMV acute infection. Nishikawa J. Et al. (2011) (11) consider that the acute infection with EBV can trigger a cross-reactance reaction with the synthesis of anti M protein antibodies of other herpes viruses. Guerrero-Ramos A et al.(2015) (12) have verified the efficiency of the Architect EBV panel in isolated infections or EBV-CMV co-infections. Testing for CMV is strongly recomended for the interpretation of a EBV infection model.

Conclusions

1. CMV + EBV co-infection has different expresion depending on the age of the pediatric patients.
2. Young age associates the subtle elements (fever, tonsilitis) amid a satisfactory general state
3. The adolescence shows an intense mononucleosic syndrome with complex clinical elements and severity stages. Hepatitis occurs mainly in this situation.
4. In atypical, subtle or severe IM forms there is probably a multiple etiology.
5. There is a suspicion of a reciprocal latent activation by an active infection both for EBV and CMV. Therefore this aspect needs further investigation.

References

1. Bravender T - Epstein-Barr virus, cytomegalovirus, and infectious mononucleosis. Adolesc Med State Art Rev. 2010 Aug;21(2):251-64
2. Chan CW, Chiang AK, Chan RH, Lau AS. Epstein--Barr virus-associated infectious mononucleosis in Chinese children. Pediatr Infect Dis J. 2003;22:974–978.
3. Chan KH, Luo RX, Chen HL, NG MH, Seto WH, Peiris JSM. Development and evaluation of an Epstein-Barr Virus (EBV) immunoglobulin M enzyme-linked immunosorbent assay based on the 18-KDa matrix protein for diagnosis of primary EBV infection. J Clin Microbiol. 1998;36:3359–3361
4. Chan KH, Tam JS, Peiris JS, Seto WH, Ng MH. Epstein-Barr virus (EBV) infection in infancy. J Clin Virol. 2001;21:57–62.
5. Choi EH, Lee HJ, Kim SJ, Eun BW, Kim NH, Lee JA, Lee JH, Song EK, Kim SH, Park JY, Sung JY. The association of newly identified respiratory viruses with lower respiratory tract infections in Korean children, 2000-2005. Clin Infect Dis. 2006;43:585–592
6. Cohen JI. Epstein-Barr virus infection. N Engl J Med. 2000;343:481–492.
7. Ito Y, Shibata-Watanabe Y, Kawada J, Maruyama K, Yagasaki H, Kojima S, Kimura H. Cytomegalovirus and Epstein-Barr virus coinfection in three toddlers with prolonged illnesses. J Med Virol. 2009;81:1399–1402.
8. Macsween KF, Crowford DH. Epstein Barr Virus recent advances. Lancet Infect Dis. 2003;3:131–140.
9. Mocarski ES, Shenk T, Pass RF. In: Fields Virology. 5. Knipe DM, Howley PM, editor. Lippincott Williams & Wilkins, Philadelphia; 2007. Cytomegaloviruses; pp. 2701–72.
10. Olson D1, Huntington MK.- Co-infection with cytomegalovirus and Epstein-Barr virus in mononucleosis: case report and review of literature D Med. 2009 Sep;62(9):349, 351-3.
11. Nishikawa J, Funada H, Miyazaki T, Fujinami H, Miyazono T, Murakami J, Kudo T, Sugiyama T. Infectious mononucleosis with atypical manifestations accompanied by transient IgM antibody response for cytomegalovirus. J Infect Chemother. 2011 Oct;17(5):686-8
12. Guerrero-Ramos A1, Patel M2, Kadakia K2, Haque T2. Performance of the architect EBV antibody panel for determination of Epstein-Barr virus infection stage in immunocompetent adolescents and young adults with clinical suspicion of infectious mononucleosis. Clin Vaccine Immunol. 2014 Jun;21(6):817-23.

13. Wang et al.: Coinfection with EBV/CMV and other respiratory agents in children with suspected infectious mononucleosis. Virology Journal 2010 7:247.
14. Zenda T, Itoh Y, Takayama Y, Masunaga T, Asaka S, Oiwake H, Shinozaki K, Takeda R. Significant liver injury with dual positive IgM antibody to Epstein-Barr virus and cytomegalovirus as a puzzling initial manifestation of infectious mononucleosis. Intern Med. 2004 Apr;43(4):340-3.

Correspondence to:
Simona Dumitra,
Clinica de Pediatrie Arad,
Victoriei 1-3,
310158,
Arad
România
E-mail: dumitrasimona@yahoo.com

NEONATES AND BLOOD TRANSFUSIONS

Mihaela Demetrian[1,2*], Constantin Ilie[1], Anca Panaitescu[2], Georgeta Grecu[2], Andra Pirnuta[2]

Abstract

This article tries to revise the rationale behind PRBC transfusions, summarize studies evaluating the efficacy of restrictive transfusion guidelines and provide methods and suggested guidelines for reducing the number of transfusions. We considered that the need of transfusion should be individualized for each clinical case. We propose a different approach for neonatal transfusion based on postnatal age, clinical status, respiratory disease, need for oxygen for sick or normal growing preterm babies.

Key words: anemia, transfusion, neonates, preterm

Introduction

Hospitalised neonates, especially preterm infants in the NICUs, receive the highest amount of blood transfusions of any hospitalised patient group. During the first 2 weeks of life when blood loss is frequent, approximately 50% of ELBW preterms (birth weight under 1000 g) will receive their first transfusion. By the end of hospitalization, more than 80% of ELBW will receive at least one transfusion. Although the number of transfusions received by preterms remains significant, it has decreased in the last 20 years, mainly because restrictive transfusion guidelines have been instituted. Although blood product transfusions have been an integral part in the treatment of newborns hospitalised in NICUs, transfusion guidelines remain controversial because most of them are extrapolated from adult guidelines or based on small studies with limited statistical significance.

Indications for red cell red transfusions

The main purpose of a red cell transfusion is to increase the oxygen delivery to the tissues. Oxygen delivery (DO2) can be quantified as the product of cardiac output (CO) and arterial oxygen content (CaO2):

$$CO(dl/min) \times CaO2(ml/dl) = DO2(ml/min)$$

Arterial oxygen content is determined by the hemoglobin concentration, the arterial blood oxygen saturation (%), the oxygen carrying capacity of hemoglobin (ml/g x g/dl, Hgb), and the solubility of oxygen in plasma (in ml/dl): CaO2=(SaO2 x 1,34 x {Hgb}) + (0,0031 x PaO2)

Improving cardiac output, hemoglobin concentration, or arterial oxygen saturation increases oxygen delivery to tissues. If the cardiac output and oxygen saturation are both optimised, the only way to deliver more oxygen to tissues is to increase hemoglobin concentrations by increasing the erithrocyte count. In young, healthy adults the critical limit below which oxygen release is equal to oxygen consumption is less than 7,3 ml oxygen/kg/min(1,2). Under this value, any decrease in oxygen delivery means a decrease in oxygen consumption and tissue hypoxia. The ratio of oxygen consumption to oxygen delivery is known as the oxygen extraction ratio and generally ranges from 0,15 to 0,33, meaning that the body consumes 15-33% of the oxygen delivered. When the extraction ratio reaches or exceeds 0.4, organ and cellular functions begin to deteriorate (3). Neonates have the added disadvantages of high values of fetal hemoglobin, low concentrations of 2,3DPG, and an accelerated weight-gain curve. Despite these characteristics, newborns have an increased capacity to compensate a gradual decrease in hemoglobin. For example, neonates born with hemoglobin concentrations less than 4g/dl as a result of cronic and severe maternal hemorrhage can appear to be well compensated for this value, and oxygen delivery appears to be adequate, in that the infant has a normal heart rate, normal perfusion and no metabolic acidosis (4). Anemia occurs when the number of erythrocites cannot meet tissue oxygen demands, the current treatment of anemia being a red cell transfusion. The difficulty comes in distinguishing between anemic newborns that require immediate transfusions of red cell and newborns with a low hematocrit. They mainly refer to rates of decrease, rather than „treshold" hemoglobin values. Neonates with significant acute blood loss require the immediate replacement of lost blood volumes but may or may not require a PRC transfusion. The newborn with a hemoglobin of 10g/dl following volume expansion may have an adequate release of oxygen to tissues and may only require iron supplementation to restore iron deposits lost during blood loss. In order to determine the blood volume that has been lost during an acute hemorrhage, the following formula can be used (5):

$$\text{PRC volume to be transfused} = 1.6 \times W \times (\text{desired hematocrit} - \text{patient's hematocrit})$$

[1]Victor Babes University of Medicine and Pharmacy, Timisoara, *PhD Student
[2]Clinical Hospital of Obstetrics and Gynecology, "Filantropia" Bucharest – Neonatal Department
E-mail: mdemetrian@yahoo.com, constantinilie@umft.ro, panaitescu.anca@yahoo.com, grecugeorgeta@yahoo.com, andrapirnuta@gmail.com

Therefore, a full term newborn weighting 3 kg with an acute drop in hematocrit at birth to 20% will need 120 ml PRBCs to achieve a desired hematocrit to 45%. It's very important to determine if the hematocrit fall is acute or chronic. A newborn with twin-to-twin transfusion syndrome or with chronic materno-fetal hemorrhage may be well compensated at birth, even if the hematocrit is below 20%. All neonates undergo a natural adaptation to extrauterine life that allows them to compensate for a gradual decrease in hematocrit. Immediately after birth increased oxygenation results in systemic oxygen delivery that far exceeds the tissues' demand for oxygen. Transfusions affect the newborns' erythropoiesis and the decision to transfuse must not be based solely on hemoglobin levels. For newborns with exchange transfusions or multiple transfusions, both the EPO levels and reticulocyte count are low at any hemoglobin value. It's known that oxygen release is low at newborns because of the higher affinity of fetal hemoglobin. In fact, a leftward shift in the hemoglobin-oxygen dissociation curve due to high level of fetal hemoglobin can maintain a better oxygen delivery during episodes of severe hypoxemia (6,7).

Blood product transfusions represent a high risk for transmitting infectious diseases, especially CMV, bacterial contamination, possible immunosupressive effect, alloimunization related to erythrocite, thrombocite and leucocyte antigens, as well as host rejection associated with significant long term comorbidity (8,9). For these reasons, an important role is played by erythropoietin in lowering transfusions in anemia of prematurity. Still, the long-term safety of erythropoietin, efficacy and cost have not been well established in this context.

PRBC transfusion guidelines are more conservative now than in the past, and volume/volume replacement of phlebotomy blood loss is less used. Micro-sampling devices that use infinitesimal quantities of blood, in-line blood sampling and clinical monitoring are used. If small volume blood transfusions are required, it is necessary to reduce the exposure to multiple donors.Transfusion therapy must be individualized to every preterm, based on clinical status and institutional transfusion resources. Any guide has set acceptable clinical circumstances for transfusion conditions but not absolute in terms of indications.When considering a transfusion in a preterm infant with a low hematocrit (in the absence of acute hemorrhage), the clinician should first determine whether the infant needs an immediate increase in oxygen delivery. If the answer is **yes**, the treatment is to transfuse PRBC. If the infant's hematocrit is greater than 25% and further flebotomy losses are estimated to be minimal, a volume of 15 ml/kg can be administered. All other infants receive 20 ml/kg. If there is no evidence that suggests an immediate increase of oxygen delivery to the tissues, then treatment with red cell growth factors such as erythropoietin, nutritive substrate, iron therapy, folate, and vitamin E might be considered (Fig. 1).

The infant should be monitored for signs of anemia because the process stimulating erythropoiesis requires at least a week to increase reticulocyte count, and it"s possible that hemoglobin level won"t rise significantly during this period (10).

All neonates undergo a natural adaptation to extrauterine life that allows them to compensate for a gradual decrease in hematocrit. Immediately after birth increased oxygenation results in systemic oxygen delivery that far exceeds the tissues' demand for oxygen. The increased need for transfusions in preterms is mainly owed to: multiple blood drawing for diagnostic testing that reduces the relative blood volume, postnatal anemia as a result of cardiovascular compromise, limited or delayed bone marrow response to different situations of hematologic stress.

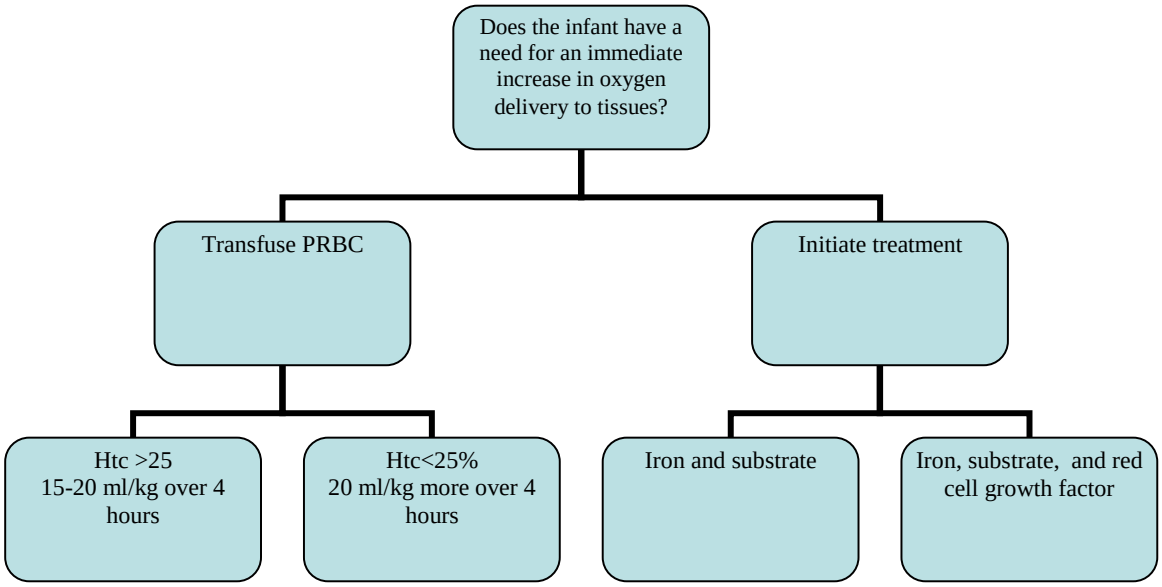

Fig.1. An approach to neonatal transfusions.

Suggestions for reducing transfusions in ELBW preterms

When a premature birth is expected (<32 weeks GA), an action plan to reduce the number of transfusions can be created. The plan consists of a few measures like: delayed clamping of the umbilical cord, administering erythrocyte growth factor and iron therapy, judicious laboratory testing that uses micro-sampling and restrictive transfusion policies (11)

- Discuss delayed cord clamping with the obstetrician and document the plan in the mother's chart. After birth the newborn should be placed below the placenta while the umbilical cord is intact for 30-45 seconds (16)
- Initiate rHuEPO treatment during the first day of life. It can be administered either as s.c 400U/kg injection or I.V. 200U/kg in a protein-containing solution (D5% solution with 2% aminoacids), to run over 4-24h (17-19)
- Administer parenteral iron, 3mg/kg once a week or 0,5mg/kg/day(added to TPN or administered IV over 4-6 h) until the infant is tolerating adequate volume feedings, then administer oral iron at 6mg/kg/day
- Use micro sampling in laboratory testing to reduce phlebotomy volumes. Order blood tests judiciously
- Replace central line asw soon as possible
- Monitor daily losses due to phlebotomy
- Report the lowest hemoglobin or hematocrit value that can be tolerated, for a variety of clinical scenarios, and age in days, for example (20-21):
  - Newborn with 100% FiO2, significant ventilatory support, vasopressors, metabolic acidosis
  - Newborn under minimal CPAP ventilatory support
  - Newborn with enteral feeding that requires oxygen
  - Newborn with enteral feeding, adequate growth, no need for oxygen supplementation
- Adapt these scenarios to the postnatal age of the neonate (under 2 weeks, 2-4 weeks, older than 4 weeks) (Table 1)

Table 1. Blood tests for ELBW.

•CBC (0,3ml) •Blood cultures (1ml) •Blood type and Rh (0,5ml) •AGS at birth (0,25ml)	•Electrolytes, blood glucose, calcemia – micro sampling or ABG (0,25ml) •Bilirubinemia only in early 0AB/Rh incompatibility jaundice (1ml) •C reactive protein only if infectious risk is present or signs of infection (1ml)	•CBC, reticulocyte count, sideremia •Blood cultures (in case of clinical signs of infection) •C reactive protein (in case of clinical signs of infection) •Complete chemistry panel if the neonate is in TPN •If not: micro sampling

- The hematocrit must be determined at birth or at the NICU. Blood drawn must be venous or arterial, never capillary. Another hematocrit determination will be made only under special circumstances
- Transfusions must be considered only if an acute >10% blood loss is apparent, asociated with signs of low oxygen release, or significant hemohrrage over 20% total blood volume
- Transfusions must be considered if there is an immediate need to increase oxygen availability to tissues. The main goal of PRC transfusions is to increase this availability
- Improving CO, hemoglobin concentration or arterial blood O2 saturation all increase O2 availability to tissues. If CO and oxygen saturation are optimised, the only way to release more oxygen to the tissues is to increase hemoglobin concentration by increasing red cell mass.
- While treating a low hematocrit preterm(without acute hemohrrage) we must ask ourseleves if an immediate increase in oxygen availability is needed:
  - If the answer is YES, treatment consists in PRBC transfusions
  - If the answer is NO, treatment with EGF and nutritive substrate plus added iron, folic acid and vitamin E must be taken into consideration. The newborn must be monitored closely for signs of anemia because it takes at least a week for the

erythropoiesis to significantly increase the reticulocyte count, and hemoglobin concentration may not increase during that time

- Newborns must be transfused with 10-20ml/kg PRBC, less if Htc>29%. A 20ml/kg volume can be used if an important phlebotomy is anticipated in ELBW preterms.
- For newborns that receive erythropoiein the rate of hemoglobin/hematocrit decrease, reticulocyte count, postnatal age and the need for oxygen must be taken into consideration
- Central measuring of Hgb/Htc are preffered; alternatively, capillary blood measurements can be taken after adequate warming of the heel.

Transfusions must be taken into consideration in the following circumstances

1. For newborns that require moderate or significant mechanical ventilation, defined as MAP>8 cm H2O and FiO2>40% in conventional ventilation, or MAP>14 and FiO2>40% in high frequency ventilation, transfusions must be taken into consideration if Htc<38%(Hb<12g/dl)
2. For newborns that require minimal ventilation, defined as MAP<8 cm H2O and/or FiO2<40% or MAP<14 cm H2O and/or FiO2<40% HFV, transfusion must be taken into consideration if Htc<35%(Hb<10g/dl)
3. For newborns that only require oxygen therapy, transfusions can be considered if Htc<25%(Hb<7g/dl) and at least one of the following symptoms is present
   a. >24 hours tachycardia(HR>180) or tachypnea (RF>60)
   b. Oxygen needs doubled in the last 48hrs
   c. Lactate>2,5mEq/l or metabolic acidosis(pH<7,20)
   d. Weight gain <10g/kg/day in the last 4 days while receiving >120kcal/kg/day
   e. Major surgery in the next 72 hours
4. For newborns without any symptoms, transfusions can be considered if Htc<20% (Hb<6g/dl) associated with an absolute reticulocyte count <100.000/microliter(2%)

We suggest lowering the need for transfusions by minimizing routine labs (flebotomy) and a more restrictive guideline. Maybe an alternative treatment (erythropoetin, nutritive substrate, iron therapy, folate and vitamin E) for anemia can be used initially, reducing to a minimum the need for blood product transfusion - (table 2).

Table 2. Anemia of prematurity – An approach.

Limiting Phlebotomy

Minimizing **routine** labs.

• Daily report of total phlebotomy

• in-line blood sampling for ABG,Na, K,Hct if BW<750 grams or you are expecting monitoring the above at least every 4 hours.

Handling PRBC

• Assign bag:

.tinu nwo eviecer lliw smarg 057 ≥*

*>750 grams will share a unit with up to 2 babies.

• PRBC should be irradiated, CMV negative and leucoreduced.

Erythropoetin
Start time/ Duration: Birth weight up to 750grams - by DOL 14 for 6 weeks. Birth weight 751-1250grams - by DOL 7 for 4 weeks.
Dose: 250-400 unit/kg/dose three times a week…M/W/F between 10-11am (in order to batch the doses). Start baby on the nearest dosing day base on the above criteria. May give IV (if on TPN) or SQ (if on full feed).

• **Preparation:**

– Subcutaneous: give undiluted (2000 unit/ml)
– IV: Dilute 2 ml (2000 unit/ml) with 8 ml normal saline to make a final concentration of 400 units/ml. DO NOT SHAKE. Dose will be diluted and GIVE IMMEDIATELY over 4 hours. IV infusion is compatible with TPN

• **Iron and Vitamin E:** Supplement during rHu – EPO treatment.
– If PO feeding volume ≤ 20ml/kg/day: Iron dextran IV 1mg/kg/day in TPN (amino acid concentration must be ≥2%)
– If PO feeding volume > 20ml/kg/day: PO Ferrous sulfate 3 mg/kg/day + vitamin E 5 IU/day.
– If all PO feeding : Ferrous sulfate 6 mg/kg/day + vitamin E 10 IU/day.

Conclusions

Blood product transfusions represent a high risk for transmitting infectious diseases, possible immunosupressive effect, alloimunization, as well as host rejection associated with significant long term comorbidity.

Transfusions should be reserved just for selected cases (newborns on mechanical ventilation, newborns on oxygen therapy that meet specific criteria, acute blood loss) with the immediate need to increase oxygen availability to tissues.

References

1. Lieberman JA, Weiskopf RB, Kelley SD et al. Critical oxygen delivery in conscious human in less than 7,3 ml O2 kg(-1). Anestesiology 92:407,2000
2. Madjdpour C, Spahn DR, Weiskopf RB. Anemia and perioperative red blood cell transfusion: A matter of tolerance. Crit. Care Med 34:S102, 2006.
3. Alverson DC. The phisiologic impact of anemia in neonate. Clin Perinatol 22:609, 1995.
4. Willis C, Forman CS Jr. Chronic massive fetomaternal hemorrhage: a case report. Obstet Gynecol 71:459, 1988.
5. Morris KP, Naqvi N, Davies P, et al. A new formula for blood transfusion volume in the critically ill. Arch Dis Child 90:724, 2005.
6. Brown MS, Garcia JF, Phibbs, RH, et al. Decreased response of plasma immunoreactive erythropoietin to „available oxygen" in anemia of prematurity. J Pediatr 105:793, 1984.
7. Stockam JA, Graeber JE, Clark DA, et al. Anemia of prematurity:Determinants of the erythropoietin response. J Pediatr 105:786, 1984.
8. Dodd, R.Y. Notari, E.P. Stramer, S.L., Current prevalence and incidence of infectious disease markers and estimated window period risk. Transfusion 2002; 42:975-979.
9. Lieb, L.E. Mundy, T.M. Goldfinger, D., et al. Unrecognized human deficiency virus type 1 infection in a cohort af transfused neonates: a retrospective investigation. Pediatrics;1995;95:717-721.
10. Robin K. Ohls, MD Why, when and how should we provide red cell transfusions to neonates. Hematology, Immunology and Infectious Disease; Neonatology questions and controversies, 4: 44-55, 2008.
11. Bifano EM. The effect of hematocrit (HCT) level on clinical outcomes in Extremely Low Birthweight (ELBW) infants. Pediatr Res 49:311A, 2001.
12. Armano R, Gauvin F, Ducruet T, et al. Determinants of red blood cell transfusions in a pediatric critical care unit: a prospective, descriptive epidemiological study. Crit Care Med 33:2637, 2005.
13. Bell EF, Strauss RG, Widness JA. Randomized trial of liberal versus restrictive guidelines for red blood cell transfusion in preterm infants. Pediatrics 115:1685, 2005.
14. Boedy RF, Mathew OP. Letter to editor:Randomized trial of liberal versus restrictive guidelines for red blood transfusions in preterm infants. Pediatrics 115:1685, 2005.
15. Murray N, Roberts I, Stanworth S. Letter to editor: Red blood transfusions in neonate, Pediatrics, 116:1609, 2005.
16. Rabe H, Reynolds G, Diaz-Rossello J. Early versus delayed umbilical cord clamping in preterm infants. Cochrane Database Syst Rev.2004;(4):CD003248.
17. Ohls RK, Ehrenkranz RA. Et al. Effect of early erythropoietin therapy on the transfusion requirements of preterm infants below 1250 grams birth weight: a multicenter, randomized, controlled trail. Pediatrics 2001;108:934-942.
18. Maier R, Obladen M et al. Early treatment with erythropoietin betha ameliorates anemia and reduces transfusion requirement in infants with birth weight below 1000g. J Pediatr 2002;141:8-15.
19. Donato H, Vain N et al. Effect of early versus late administration of human recombinant erythropoietin on transfusion requirements in premature infants: result of a randomized, placebo-controlled, multicenter trail. Pediatrics 2000;105:1066-1072.
20. Mock DM, Bell EF, Lankford GL. Hematocrit correlates well with circulating red blood cell volume in very low birth weight infants. Pediatr Res 2001;50:525–31
21. Morris KP, Naqvi N, Davies P, et al. A new formula for blood transfusion volume in the critically ill. Arch Dis Child 90:724, 2005.

Correspondence to:

Mihaela Demetrian,
Clinical Hospital of Obstetrics and Gynecology
"Filantropia" Bucharest – Neonatal Department
Bd. Ion Mihalache, Nr. 11
Bucharest, Romania
E-mail: mdemetrian@yahoo.com

THE NEED FOR VENTILATORY SUPPORT AND SURFACTANT ADMINISTRATION IN PREMATURE INFANTS WITH NEONATAL RESPIRATORY DISTRESS

Andreea Fratila[1*], Daniela Iacob[1], C. Ilie[1]

Abstract

Ventilatory support is often necessary to preterm infants due to pulmonary immaturity and associated pathology. Frequently these premature infants also require surfactant administration. Using ventilatory support makes the prognosis in this group of infants to be favorable in most cases.

We performed a retrospective study between January 1, 2008 and December 31, 2013 attended by 483 premature infants who had neonatal respiratory distress syndrome from the total of 1,045 premature infants born in this period.

Neonatal respiratory distress syndromes significantly contribute to morbidity and mortality of premature infants. Ventilatory support is used in cases requiring respiratory support to premature infants. Also, surfactant administration is one of the few therapies that greatly changed the clinical practice in neonatology. Surfactant therapy decreased neonatal mortality by respiratory distress.

Key words: neonatal respiratory distress, prematurity, surfactant, ventilatory support

Introduction

Premature babies continue to be one of the biggest challenges of neonatologists. Respiratory distress syndrome (RDS) is one of the most common respiratory disease and a major cause of neonatal mortality. Prematurity is the most important risk factor for the appearance of respiratory distress syndrome. The incidence of respiratory distress syndrome decreases with gestational age increasing.

Neonatal respiratory distress syndrome occurs due to lung immaturity, especially because primary surfactant deficiency. The main goals of the therapy which involves infants with respiratory distress syndrome are ventilator support and surfactant administration. Surfactant therapy reduced mortality due to respiratory distress syndrome in preterm infants about 50%.

Trends in neonatal ventilation therapy is the use of non-invasive ventilation (CPAP) whenever possible and invasive ventilation (IPPV, SIMV, HFOV) when it is absolutely necessary to support premature infants breathing.

Objectives

This paper aims to highlight the incidence and severity of neonatal respiratory distress syndrome, the use of ventilatory support and surfactant administration in a group of premature infants who developed respiratory distress syndrome.

Material and Methods

The study was conducted at the Clinic of Neonatology "" Bega "Timisoara for a period of six years, between 2008-2013.

From the total of 1,045 premature infants with gestational age below 37 weeks born in this period, 483 premature infants who presented neonatal respiratory distress syndrome were introduced in the study.

The work method was represented by retrospective analysis of patients' observations papers. The study included infants who presented respiratory distress syndrome. We gathered data from each patient , like : year of birth, gestational age, sex, birth weight, Apgar score, mode of delivery, presentation, severity of respiratory distress syndrome, need for ventilatory support, mode of mechanical ventilation, surfactant administration, blood product administration, use of ventilation with mask and balloon in the delivery room, maternal corticosteroid administration and patient evolution.

Results and discussions

Between 1 January 2008 and 31 December 2013, in the Department of Neonatology "Bega" Timisoara, were born a total of 1,045 premature infants under 37 weeks gestational age, of which 483 premature infants developed respiratory distress syndrome. 163 premature infants had mild form of respiratory distress, 123 premature infants had medium form of respiratory distress and 197 premature infants had respiratory distress severe form. We observe that infants who presented severe form of respiratory distress had a higher prevalence (41%). (Fig. 1)

[1]University of Medicine and Pharmacy Timisoara-Romania, Department of Neonatology
[*]PhD Student
E-mail: andreeabg@yahoo.com, danielariacob@yahoo.com, constantinilie@umft.ro

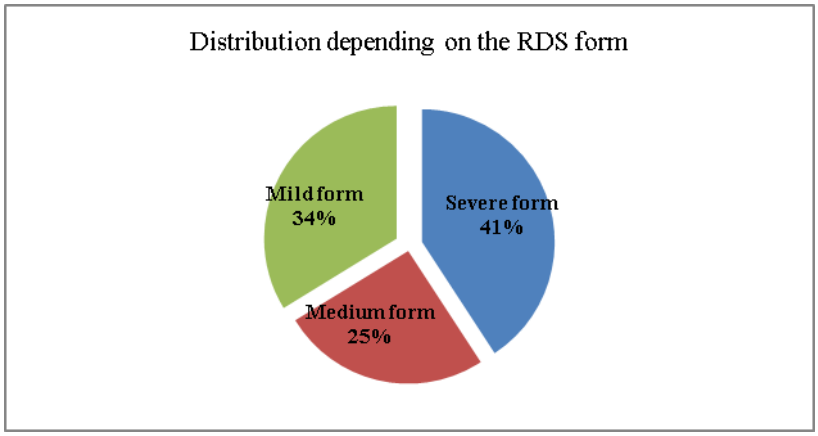

Fig. 1. Distribution of cases depending on the RDS form.

The distribution of the premature infants per year was: 2008-65 cases , 2009-72 cases , 2010-65 cases, 2011-103 cases, 2012-100 cases and 2013-78 cases. The distribution by gender was: 43% females and 57% males. We see a greater predisposition of males in the occurrence of respiratory distress syndrome.

Premature infants with respiratory distress syndrome who come by Caesarean section had a higher prevalence, 75% versus 25% who come by natural birth. Regarding to presentations, 361 premature infants were in cranial presentation, 91 premature infants were in pelvic presentation and 31 preterm infants were in transverse presentation.

Another criterion was gestational age. Most numerous premature infants were between 30-32 weeks - 37% , between 33-34 weeks - 24% , between 27-29 weeks -16% , between 35-36 weeks - 13% and between 24-26 weeks - 10% . (Fig. 2)

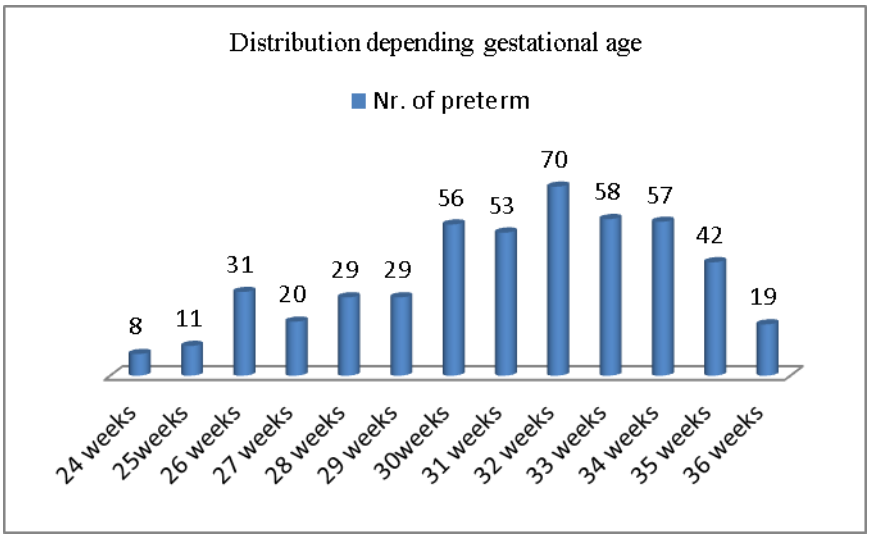

Fig. 2. Distribution of cases depending gestational age.

Another criterion was the Apgar score. Thus, there were 18 cases with Apgar score 1, 19 cases with Apgar score 2, 28 cases Apgar score 3, 31 cases with Apgar 4, 67 cases with Apgar 5, 60 cases with Apgar 6 , 128 cases Apgar 7 , 101 cases with Apgar 8 and 31 cases with Apgar 9. Distribution by birth weight was: under 1000 g = 15% 1000-1499g = 26%, 1500-1999g = 32% , 2000-2499g = 19% , over 2500g = 8%. Can be observed a higher prevalence in premature infants with birth weight between 1500-1999 g.

In the group studied 317 premature infants required positive pressure ventilation with mask and balloon at birth. Surfactant received 121 premature infants. Maternal antenatal corticosteroids were administered to 170 cases. Noninvasive ventilatory support (nCPAP) required 159 premature infants. In this study group 199 premature infants (41%) needed mechanical ventilation for respiratory support. Mechanical ventilation IPPV mode required 195 premature infants in the study group and 72 premature infants required SIMV mode. The duration of mechanical ventilation was 1-5 days in 126 cases (64%) , 6-10 days in 49 cases (25%), 11 to 15 days in 13 cases (6%), 16 to 23 days in 8 cases (4%) and between 28-43 days in 2 cases (1%). (Fig.3)

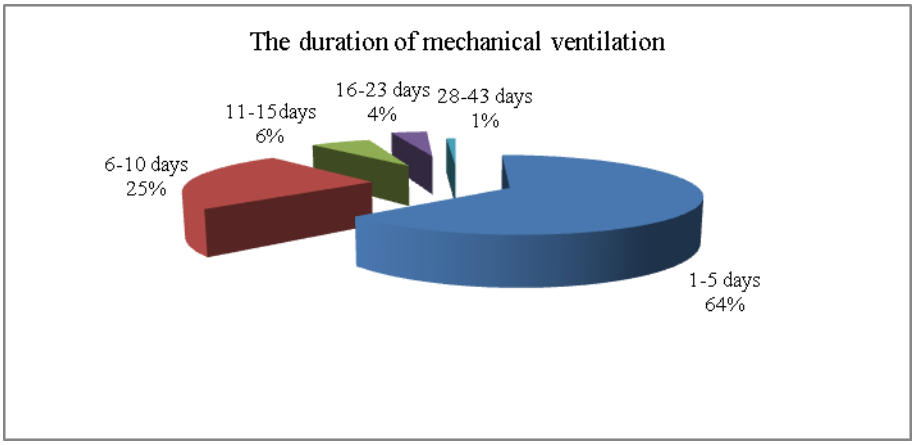

Fig. 3. The duration of mechanical ventilation.

Premature infants require in the majority also blood product administration. So, 169 cases received packed red blood cells, platelet received 71 premature infants , and fresh plasma received 233 premature infants.We notice that fresh plasma received a higher number of premature infants.

The evolution of premature infants relies on several factors. In the study group, 78% of premature infants had a favorable outcome and 22% of the cases had an unfavorable outcome.

Conclusions

1. Risk factors that increase the risk of respiratory distress syndrome are small gestational age, male sex, low birth weight, low Apgar score, caesarean section.

2. Most numerous premature infants were between 30-32 weeks.

3. Ventilatory support is needed more frequently to preterm babyes due to pulmonary immaturity and associated pathology.

4. Ventilatory support makes the prognosis of the premature infants favorable in the most of cases.

5. Premature infants required both invasive ventilatory support and noninvasive ventilatory support.

6. Mechanical ventilation in the IPPV mode was used more often than SIMV mode in our study group.

7. Early administration of surfactant decreases the incidence of complications, the duration of hospitalization and also increase survival of the premature infants.

References

1. Sweet D, Bevilacqua G, Carnielli V, Greisen G, Plavka R, Saugstad OD,Simeoni U, Speer CP, Valls ISA, Halliday H: European consensus guidelines on the management of neonatal respiratory distress syndrome. J Perinat Med 2007, 35:175-186.
2. Sweet DG, Carnielli V, Greisen G, Hallman M, Ozek E, Plavka R, Saugstad OD, Simeoni U, Speer CP, Halliday HL, European Association of Perinatal M: European consensus guidelines on the management of neonatal respiratory distress syndrome in preterm infants - 2010 update. Neonatology 2010, 97:402-417.
3. Diblasi RM: Nasal continuous positive airway pressure (CPAP) for the respiratory care of the newborn infant. Respir Care 2009, 54:1209-1235
4. Sweet D, Bevilacqua G, Carnielli V, Greisen G, Plavka R, Saugstad OD,Simeoni U, Speer CP, Valls ISA, Halliday H: European consensus guidelines on the management of neonatal respiratory distress syndrome. J Perinat Med 2007, 35:175-186.
5. Bohlin K, Jonsson B, Gustafsson A, Blennow M. Continuous positive airway pressure and surfactant. Neonatol. 2008;93:309–315. doi: 10.1159/000121457.
6. Sweet D, Bevilacqua G, Carnielli V, Greisen G, Plavka R, Saugstad OD,Simeoni U, Speer CP, Valls ISA, Halliday H: European consensus guidelines on the management of neonatal respiratory distress syndrome. J Perinat Med 2007, 35:175-186
7. Greenough A, Donn SM. Matching ventilatory support strategies to respiratory pathophysiology.Clin Perinatol. 2007 mar;34(1):35-53, V-VI.
8. Pillow J, Travadi JN (2005) Bubble CPAP: is the noise important? An in vitro study. Pediatr Res 57:826–830
9. Steven M Donn MD and Sunil K Sinha MD PhD-Invasive and Noninvasive Neonatal Mechanical Ventilation ,Respiratory Care • april 2003 vol 48 nr 4
10. Greeenough A, Milner AD, Dimitriou G – Synchronized ventilation. The Cochrane database. Oxford; 2005)
11. Shoemaker MT, Pierce MR, Yoder BA, DiGeronimo RJ (2007) High flow nasal cannula versus nasal CPAP for neonatal respiratory disease: a retrospective study. J Perinatol 27:85–91
12. Stoicescu S: Boli pulmonare neonatale. Ed Universitara Carol Davila Bucuresti 2009
13. Kotecha S, Allen J. Oxygen therapy for infants with chronic lung disease. Arch Dis Child Fetal Neonatal Ed. 2002;87:F11–F14

14. Hibbard J, Wilkins I, Sun L, Gregory K, Haberman S, Hoffman M, et al. Respiratory morbidity in late preterm births. JAMA Journal of the American Medical Association. 2010;304:419–425
15. Bishop NB, Stankiewicz P, Steinhorn RH. Alveolar capillary dysplasia. American Journal of Respiratory and Critical Care Medicine.2011;184:172–179
16. Sweet D, Bevilacqua G, Carnielli V, Greisen G, Plavka R, Saugstad OD, et al. European consensus guidelines on the management of neonatal respiratory distress syndrome. Neonatology. 2013 ;103:353-368
17. Joshi S, Kotecha S. Lung growth and development. Early Hum Dev. 2007;83:789–794
18. William H. Tooley Intensive Care Nursery at UCSF Medical Center Intensive Care Nursery House Staff Manual. 79. 2004 The Regents of the University of California. Respiratory Distress Syndrome (RDS).
19. Gomella TL, M. Cunningham. 2009. Neonatology: management, procedures, on-call problems, diseases and drugs. (6th ed), 48-67

Correspondence to:
Daniela Iacob
"Victor Babes" University of Medicine and Pharmacy
Timisoara – Department of Neonatology
E. Murgu, Nr. 2
Timişoara, România
E-mail: danielariacob@yahoo.com

SEVERE CASES OF PEDIATRIC TUBERCULOSIS

Ariadna Petronela Fildan[1], Doina Tofolean[1], Claudia Toma[2], Emanuela Tudorache[3], Elena Dantes[4]

Abstract

Pediatric tuberculosis (TB) represent a warning sign in a community, as it could signal recent TB infection of a contagious form in an adult. Rapid diagnosis is very important for effective treatment in children, and it is mandatory for the efficient control of tuberculosis at the public health level, since it allows rapid identification of contagious adult cases. Here we report three severe cases of TB in children, one of them occurred in a HIV positive patient. These cases stress the need for an extensive medical history, a complete clinical and physical examination of the patient and radiological examination during diagnostic work-up. This includes: the positive history for contact with infected adults; the presence of risk factors; the evaluation of the immunological status; exclusion of TB diagnosis for persistent respiratory symptoms (2-3 weeks) after antibiotic therapy; the presence of radiographic abnormalities and the detection and isolation of the Mycobacterium Tuberculosis in the appropriate specimens for bacteriological examination. Early diagnosis and treatment are extremely important once tuberculosis is suspected, to improve survival and prevent morbidity.

Key words: pediatric tuberculosis, miliary, HIV infection, diabetes mellitus

Introduction

Tuberculosis (TB) is still a major public health problem worldwide. According to the latest estimation of the World Health Organization in 2014, 9.6 million new cases were reported and 1.5 million new death cases. Approximately 1.000.000 new cases of TB in children occur in children less than 15 years [1]. This high level of incidence of TB in children is probably underestimated due to the frequent involvement of individuals with poor social-economic status, that have no access to investigation and treatment, but also due to diagnostic difficulties by non-specific symptoms and bacteriological confirmation. [2,3]. Romania ranks first in the EU in the level of TB incidence, with 81/100.000 population new cases and 639 (4%) cases aged under 15 years, although there is a downward trend in the past few years [1,4]. A high level of TB epidemic is associated with an elevated incidence of infection in the general population, children being a vulnerable population. Studies show that approximately 50% of infected children are at risk to develop active disease in the absence of prophylactic treatment [5,6]. This risk is increased in the presence of favorable conditions such as immunosuppressive diseases (HIV, diabetes), hypotrophy and poor socio-economic conditions [7]. We report 3 cases with severe forms of TB in children; one with miliary, one with extensive cavitary TB, highly contagious and the last one with meningitis tuberculosis in a positive HIV patient. These cases had diagnostic, evolution and therapy particularities, all having a high degree of severity by lesion extension and the association of other pathologies that have increased the difficult therapeutic approach.

Case report 1

We present a case report of a male patient, aged 4 years, in the care of grandparents, with poor housing. The patient was admitted to the Pediatric Pulmonology Department with malaise, fever, sweating, vomiting, headache, dysphagia, anorexia, weight loss, productive cough and dyspnea at small efforts. The symptoms had an insidious onset, a month before admission, with a worsened progress. Objective - hypotrophy (BMI – 11.1 kg/m^2), pale, lips cyanosis, tachypnea. Pulmonary: vesicular murmur present, no crackles, SpO_2 88%, BP 80/50 mmHg, HR 120/min. Tuberculin skin test (TST) 5U negative PPD. Biological: ESR 51mm/h, WBC 10.000/µL, Hb 10g/dl, PLT 710.000/µL, TGO/TGP 118/58. Chest radiography (Figure 1) revealed multiple micro-nodular opacities, unorganized, pale, vague outlined, disseminated in both lung fields, with a suggestive aspect of miliary TB. Because the suspicion of meningitis has been raised, lumbar puncture was performed. Cerebrospinal fluid examination revealed negative Pandy`s reaction, element 75/mm^3, 15% nutrophils, 85% lymphocytes, acid-resistant bacilli in microscopy and culture negative. GeneXpert of gastric lavage test was negative for Mycobacterium tuberculosis. Etiology of TB sputum examination by culture on solid medium confirmed positive for BK. Negative HIV test. The final diagnosis was: Miliary tuberculosis; Acute respiratory failure; Hepatic cytoloysis.

[1]"Ovidius" University, Faculty of Medicine, Constanta, Department of Internal Medicine
[2]"Carol Davila" University of Medicine and Pharmacy, Bucharest, Department of Pneumology
[3]"Victor Babes" University of Medicine and Pharmacy, Timisoara, Department of Pneumology
[4]"Ovidius" University, Faculty of Medicine, Constanta, Department of Pneumophtysiology
E-mail: ariadnapetrofildan@yahoo.com, tofoleandoina@yahoo.com, claudiatoma@yahoo.co.uk, tudorache_emanuela@yahoo.com, elena.dantes@gmail.com

Patient followed anti-tuberculosis treatment regimen according to the National Guidelines for Prevention, Surveillance and Control of Tuberculosis with Isoniazid (HIN) 65 mg, Rifampicin (RMP) 150 mg, Pyrazinamid (PZM) 325 mg, Ethambutol (EMB) 200 mg, Hemisuccinate hydrocortisone 200/day (for a week), afterwards corticosteroid therapy with oral Prednisone 20 mg/day with progressive decrease within 4 weeks, gastric and hepatic protectors, Mannitol 20%, 500ml/day, oxygen, vital functions monitoring. Evolution was shifting with multiple episodes of acute respiratory failures and febrile exacerbations in the first two weeks of treatment, and then progressively, patient condition improved significantly.

Case report 2

Female patient aged 15 years, student in the IX class, know with type I diabetes mellitus, insulin required for over 3 years, treated with Novorapid 12 U 3 times/day and Lantus 22U at 10 pm, is hospitalized in the Pediatric Pulmonology Department for muco-purulent coughing, with insidious onset for over two months. Physical examination reveals an overweight patient, BMI- 27.5 kg/m2, paleness. Pulmonary – respiratory murmur present, no crackles, SpO2 99%, HR 120/min, BP 100/50mmHg. Biologically were observed mild anemia, severe inflammatory syndrome (Hg 11.3 g/dl, MCV 75.7 fL, MCH 23.3 pg, MCHC 30.7 g/dl, WBC 8500/µL, normal leukocity formula, Thrombocytes 373.000/µL, ESR 81 mm/h), blood glucose 383 mg/dL, urinalysis glucose >500 mg/dl, otherwise normal. Chest radiography (Figure 2) highlights stretched opacity, unorganized, comprising the upper half of the left hemi-thorax, pale, heterogeneous by the presence of multiple hyper-transparent images inside, of various sizes, suggestive for left extended cavitary pulmonary secondary tuberculosis. The case was confirmed, being positive in microscopy for acid-resistant-bacilli (+++) and rapid culture (BACTEC). Specific anti-tuberculosis therapy was initiated with a 4 drugs scheme, diet with 200 mg hydrocarbons/day, insulin therapy and hydration. Product tolerance was good, symptoms remitted after three weeks.

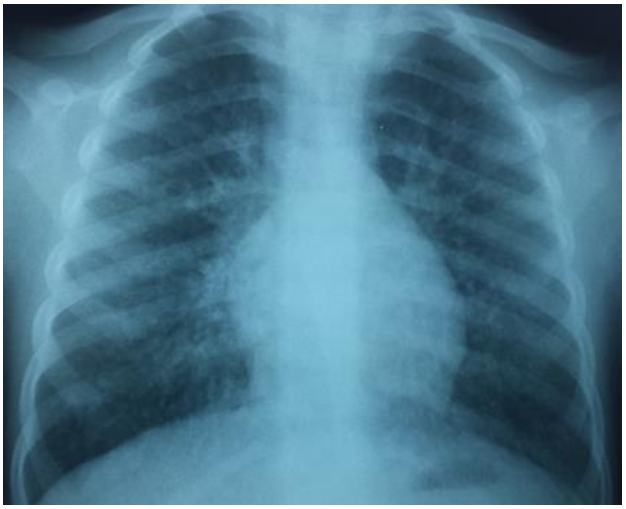

Figure 1. Chest radiograph case 1, miliary TB.

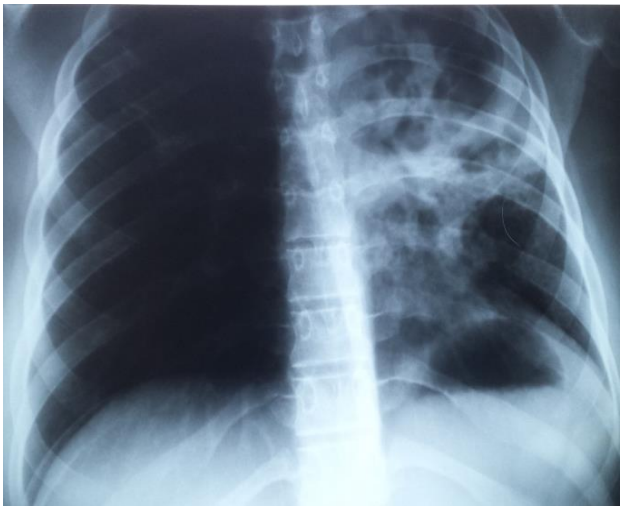

Figure 2. Chest radiograph case 2, cavitary TB.

Case report 3

We present the case of a male patient, aged 17 years, who comes in the Department of Infectious Diseases with high fever (39C), headache, chills, photophobia, neck stiffness, drowsiness, vomiting. These symptoms started insidious, 10 days before admission with progressive evolution towards aggravation into a coma in the first 12 hours of hospitalization. The patient was known to have HIV from the age of 3 years, with antiretroviral therapy instituted at the age of 10 years, with noncompliant therapy, reflected in the evolution of viral load and CD4 values (Table 1, Figure 3). Physical examination revealed severe general condition, initially conscious, collaborator, drowsiness, subsequently loss of consciousness, superficial coma (grade I). Spinal puncture revealed cloudy cerebrospinal fluid, biochemical and cytological features where suggestive for TB etiology, confirmed by positive rapid culture (BACTEC). The treatment was specific anti-tuberculosis regimen I with Isonizid 10 mg/kg/day, Rifampicin 15 mg/kg/day, Pyrazinamide 30 mg/kg/day administered rectal in suppository form and Streptomycin 15 mg/kg/day intra-muscularly. Favorable clinical evolution is slow, patient coming out of coma after 21 days. After two months intense fever and headache reappear and CSF examination reveals the presence of Cryptoccocus neoformans. Treatment was associated with Amphotericin B in dose of 0.5-0.7 mg/kg/day, for five days and afterwards Fluconazole 400 mg/day for five days, then 200 mg/day for 10 days, being discharged after 3 months of hospitalization with good general clinical condition. Discharge recommendation was to continue tuberculosis therapy under direct observation (DOTS) at home. After another 3 months of treatment, the patient returns with malaise, fever, chills, headache, nausea, legs numbness and multiple peripheral lymphadenopathy. Physical examination reveals pale skin, sinus sensitive points, with no signs of meningeal irritation.

Biologically was noted ESR 30 mm/h, fibrinogen 638 mg/dl, Hg 8.5g/dl, SGOT/SGPT 150/120. In the cerebrospinal fluid examination, genetic testing for Mycobacterium tuberculosis present BAC revealed resistant to rifampicin. Anti-tuberculosis regimen was reconsidered by associating Ofloxacin 800 mg/day, Ethambutol 1200 mg/day. Antibiotic treatment with large spectrum was associated (Ceftriaxonum 2g/day, Gentamicin 160mg/day, antimicotic (Fluconazole 400mg/day), Mannitol 20% 500ml/day, corticosteroids (Hemisuccinate hydrocortisone 200 mg/day iv). The dynamic evolution was unfavorable, with general condition gradually deteriorating, paraparesis, convulsions and seizures, loss of consciousness, coma and death in a month of hospitalization.

Table 1. Evolution of viral load between 2002-2012, case 3, TB meningitis.

Year	2002	2003	2005	2006	2008	2009	2010	2011	2012
Viral load (copies/ml)	22000	<400	<400	2720	52500	122000	116000	316	38000

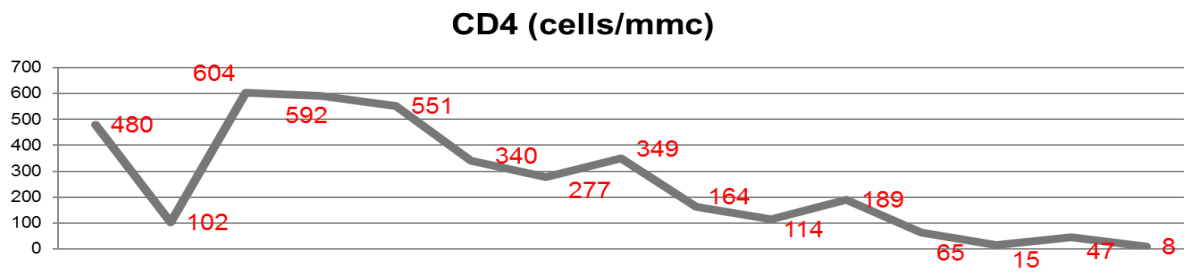

Figure 3. Variation of CD4 lymphocytes between 2002-2012, case 3, TB meningitis.

We report 3 cases, severe forms of TB in children, a case of miliary, a case of extensive cavitary TB, highly contagious and a case of meningitis tuberculosis in a patient HIV positive. The diagnosis of tuberculosis in children is a very difficult one, given that clinical presentation is often non-specific and bacteriological confirmation is obtained in less than 15% of the cases [7]. This is the main reason for a detailed assessment of all the evidence derived from a careful history of exposure, clinical examination and relevant investigations. To formulate a positive diagnosis of TB in children, the following criteria must be considered: careful history (including history of TB contact and symptoms consistent with TB); clinical examination (including growth assessment); tuberculin skin testing; chest radiography (if available); bacteriological confirmation whenever possible; investigations relevant for suspected pulmonary Tb and suspected extra-pulmonary TB [8].

In the first case we reported a miliary TB diagnosed at a very young age, only 4 years old. Risk factors in this case were hypotrophy weight and poor socioeconomic conditions. Malnutrition is associated with impaired call-mediated immunity, favoring rapid progression of TB infection to severe disease, disseminated, and threatening, as miliary asphyxia[8,9]. Moreover, living in small enclosed residences with poor ventilation increases the risk of infections in the presence of contagious TB cases [9]. Ignoring non-specific symptoms by people who care for children, their lack of health education, are also factors that can result in delayed diagnosis and disease progression to sever forms: miliary, meningitis, TB bronchopneumonia. Miliary TB is a hematogenous dissemination form of bacilli tuberculosis, child specific. It`s starting point is one of the primary component complex (lymphadenopathy caseous) and can occur in the first weeks after the initial infection [10,11]. Miliary TB is a particularly severe, disseminated disease, which can involve the lungs, meninges and/or other organs (liver, spleen, lymph nodules). In this case, to assess the implication of other organs beside the lungs, biological test was performed for the hepatic function and lumbar puncture with cerebrospinal fluid analysis. These findings have sustained the liver damage in the absence of the meninges impairment. Repeated episodes of acute respiratory failure presented by this patient can be explained by the density of the millar miconodules and by the exudative alveolar peri-micronodular reaction with inflammatory hyperergic condition. For this reason, anti-inflammatory medication, corticosteroid type, was added, which along with anti-tuberculosis therapy led to a favorable outcome.

Cavitary forms of TB, such as case 2, are usually found in adults, and their occurrence in children is a warning to the community [12]. Late discovery of a case of extended pulmonary TB, highly contagious, into a community of children, raises major epidemiological problems through both receptive hosts and the extent of epidemiological investigations. Intensive detection is to identify suspects by primary care services, school doctors, and community care network [13]. Usually child tuberculosis is a non-contagious form, but in immune-compromised cases, infection can lead to primo-secondary forms, severe, diseminated and highly contagious; cavitary lesions have between 10 million – 1 billion bacilli compared to nodular lesions that have

between 100-10000 bacilli [9]. Diabetes is a risk factor that should be an argument for careful monitoring with regular clinical checks, regardless of age [14]. The relative risk for TB among diabetic patients ranges between 2.44 - 8.33 compared to the general population [15]. Studies have shown that in patients with diabetes, anti-infective defense mechanisms are altered by reduced macrophages alveolar activation and reduced amount of interferon gamma produced by CD4 [16]. In the presented case, pulmonary tuberculosis appeared on the background of uncontrolled diabetes type 1. Insidious symptoms led to a late detection of TB, with important pulmonary parenchyma lesions through multiple cavities, extended in the left lung. The prognosis of this case is reserved, burdened by the risk of major sequelae healing with left fibrotorax, negative cavity syndromes, chronic respiratory failure, massive hemoptysis, pulmonary aspergillosis or lung suppurations. Careful monitoring of the therapeutic regimen is recommended, patient having indications for extended therapy for 8 months to 1 year, considering the pharmacological particularities given by the presence of diabetes [17]. Low concentrations of rifampicin, the changes in absorption, low protein binding medication are factors of bad therapeutic response with risk of failure and possible resistance to anti-tuberculosis therapy [18,19].

In patients with HIV, the occurrence of TB meningitis is closely related to the severity of immune depression, CD4 lymphocytes being significantly decreased. People with HIV have a 20-30 times higher risk of TB compared to healthy individuals [19]. In general, tuberculosis is the most common pathology associated with HIV infection in high endemic territories, such as in this case [20], and central nervous system TB is the most severe form of TB in this population, with a mortality up to 67% compared to 25% in immune-competent individuals [21]. Prognosis depends on the speed of diagnosis and treatment initiation [19,22]. It requires rapid exclusion of other forms of meningitis with other opportunistic pathogens (Cryptococus neoformans, Toxoplasma gondii). In our case the diagnosis was confirmed by positive bacteriological culture in liquid medium (BACTEC) within 10 days, but therapy was initiated from the first day, based on clinical suspicion and biochemical changes in the cerebro-spinal fluid. Currently, genetic tests of DNA amplification Mycobacterium (GeneXpert, LPA) may have an important role in rapid diagnosis (2 hours) of TB meningitis and resistance to Rifampicin. However, the diagnosis cannot be excluded on the basis of a negative result, sensitivity being between 50-60% [23]. In the reported case, the unfavorable evolution concluded with death can be explained, on one hand, by the existence of two diseases that negatively influence each other, and on the other hand, by the non-compliant treatment. The fact that the patient returned after three months from the first hospitalization with engraved general condition and rapid genetic testing for BK showing a resistant germ to Rifampicin, highlights the difficult therapy given by the association of the two pathologies, high risk selection of resistant germs population, increased complication risk, emphasized also by the non-compliance to therapy.

Conclusions

Tuberculosis in children raises diagnostic, treatment and monitoring problems. Early diagnosis and treatment are extremely important once tuberculosis is suspected, to improve survival and prevent morbidity. The multidisciplinary approach to these cases can lead to therapeutic success, especially for severe forms of TB.

References

1. Global Tuberculosis Report 2015, World Health Organization (WHO), Geneva, 2015, available from: http://www. who.int/tb/publications/global_report/en/index.html.
2. Nelson LJ, Wells CD. Global epidemiology of childhood tuberculosis, Int J Tuberc Lung Dis, 2004, 8(5):636–647.
3. Getahun H, Sculier D, Sismanidis C, Grzemska M, Raviglione M. Prevention, diagnosis, and treatment of tuberculosis in children and mothers: evidence for action for maternal, neonatal, and child health services, J Infect Dis, 2012, 205(Suppl 2):S216–S227.
4. Didilescu C, Cioran N, Chiotan D, Popescu G. Tuberculoza la copii in Romania, Pneumologia, 2013; 62(1):10-14.
5. Marais BJ et al. A refined symptom-based approach to diagnose pulmonary tuberculosis in children. Pediatrics, 2006, 118:e1350-1359.
6. Schaaf HS, Zumla A eds. Tuberculosis: a comprehensive clinical reference. London, UK: Saunders Elsevier, 2009.
7. Eamranond P, Jaramillo E. Tuberculosis in children: reassessing the need for improved diagnosis in global control strategies, Int J Tuberc Lung Dis, 2001, 5(7):594–603.
8. Perez-Velez CM, Marais BJ. Tuberculosis in children. New England Journal of Medicine, 2012; 367(4):348-361.
9. Vandana Batra; Chief Editor: Russell W Steele, Pediatric Tuberculosis Updated: Oct 11, 2012.
10. Sharma SK, Mohan A, Sharma A. Challenges in the diagnosis & treatment of miliary tuberculosis Indian J Med Res. 2012 May;135(5):703-30.
11. Didilescu C, Marica C. Tuberculoza - trecut, prezent,viitor. Editura Universitara Carol Davila Bucuresti, 2004,155-185, 371
12. Starke JR. New concepts in childhood tuberculosis. Curr Opin Pediatr 2007 Jun; 19(3): 306-313.
13. Ghid Metodologic de Implementare a Programului National de Prevenire, Supraveghere si Control al Tuberculozei, Bucuresti, 2015, Ed. Alpha MDN, ISBN 978-973-139-325-4;19-27

14. Stevenson CR, Forouhi NG, Roglic G, et al. Diabetes and tuberculosis: the impact of the diabetes epidemic on tuberculosis incidence. BMC Public Health 2007;7:234
15. Dooley K Chaisson R Tuberculosis and diabetes mellitus: convergence of two epidemics, Lancet Infect Dis. 2009; 9(12): 737-746
16. Moutschen MP, Scheen AJ, Lefebvre PJ. Impaired immune responses in diabetes mellitus: analysis of the factors and mechanisms involved. Relevance to the increased susceptibility of diabetic patients to specific infections. Diabetes Metab 1992;18:187–201
17. Niemi M, Backman JT, Fromm MF, Neuvonen PJ, Kivisto KT. Pharmacokinetic interactions with rifampicin: clinical relevance. Clin Pharmacokinet 2003;42:819–50.
18. Gwilt PR, Nahhas RR, Tracewell WG. The effects of diabetes mellitus on pharmacokinetics and pharmacodynamics in humans. Clin Pharmacokinet 1991;20:477–90
19. Wood R, Maartens G, Lombard CJ. Risk factors for developing tuberculosis in HIV-1-infected adults from communities with a low or very high incidence of tuberculosis. J Acquir Immune Defic Syndr 2000; 23: 75–80.
20. Croda MG, Vidal JE, Hernandez AV, et al. Tuberculous meningitis in HIV-infected patients in Brazil: clinical and laboratory characteristics and factors associated with mortality. Int J Infect Dis 2010; 14: e586–e591
21. Azuaje C, Fernandez Hidalgo N, Almirante B, et al. Tuberculous meningitis: a comparative study in relation to concurrent human immunodeficiency virus infection. Enferm Infecc Microbiol Clin 2006; 24: 245–250
22. Thwaites GE, Duc Bang N, Huy Dung N, et al. The influence of HIV infection on clinical presentation, response to treatment, and outcome in adults with tuberculous meningitis. J Infect Dis 2005; 192: 2134–2141
23. Kim CH, Hyun I, Hwang Y, Kim DG et al. Identification of Mycobacterium tuberculosis and Rifampin Resistance in Clinical Specimens Using the Xpert MTB/RIF Assay. Ann Clin Lab Sci January 2015 45:1 32-38

Correspondence to:
Doina Tofolean,
128 Mamaia Bld,
900572,
Constanţa,
România
Phone: 0722488722
E-mail: tofoleandoina@yahoo.com

LAPAROSCOPIC CHOLECYSTECTOMY IN CHILDREN – PRELIMINARY EXPERIENCE

RE Iacob[1,2], MC Popoiu[1,2], VL David[1,2], DV Vasilie[1,2], Corina Stanciulescu[1,2], Lavinia Stretcu[2], Alexandra Nyiredi[1,2], ES Boia[1,2]

Abstract

Introduction. Gallstone is a common disease in adults especially in fat people and is rarely seen in children. The aim of this study is to present our preliminary experiences and outcomes in pediatric laparoscopic cholecystectomy.

Materials and methods. The first 18 gallstones patients operated in the Pediatric Surgery Department of the Clinical Emergency Hospital for Children "Louis Turcanu" Timisoara – Romania were analyzed between (January 2013 - present). Data was collected on age, weight, gender, Body Mass Index (BMI), comorbidities, time of surgery, number of ports used, using of drain and antibiotics.

Results and discussions. The study included 14 females and 4 males patient with age ranging from 2-17 years (mean 12.7). The weight of the patients ranged between 12-73 kg (mean 49.9) with BMI ranging between 16.8-28.2 (mean 21.3). Three patients were overweight, however obesity and morbid obesity was absent in this cohort. With regards to the pathology: : 2 patients presented hypercholesterolemia, 1 patient had anemia, 1 patient cystitis, and another presented muscular dystrophy with 13 patients having no associated pathology. Out of the whole lot of patients 4 patients presented cholecystitis and one associated jaundice. In 8 patients a 3-port technique was used, while a 4-port procedure was preferred in 10 patients. Drains were placed and antibiotics administered in all patients. The most commonly used antibiotic was Ampicillin. Mean number of postop days was 4.41.

Conclusions. Interesting in our cohort was that obesity did not play a role in gallstones. Technical skills were improved during our learning curve in cholecystectomy. Our data was comparable to most other series in their learning curve.

Key words: gallstone, children, laparoscopic cholecystectomy

Introduction

Gallstone is a common disease in adults especially in overweight people and is rarely seen in children. Lately gallbladder disease has become a very common problem in children and young adolescents. Over the past 15 years the age of the pediatric patients with gallbladder disease has been gradually decreasing.[1] Historically, gallbladder disease has been frequently diagnosed in children with hemolytic cholelithiasis.

Now gallstone and biliary dyskinesia are often seen in children. These patients often present atypical symptoms, but they can also have a spectrum of symptoms that are found with gallbladder disease (right upper abdominal pain, nausea, vomiting).[1] It is defined by a completely normal gallbladder on imaging tests, typically ultrasound; and decreased gallbladder contraction in response to a pharmacological stimulus. Unlike other functional gastrointestinal disorders that are treated with behavioral therapy, medications, and/or dietary modification, current clinical practice has accepted cholecystectomy as the treatment of choice.[2]

Aim

To present our preliminary experiences and outcomes in pediatric laparoscopic cholecystectomy.

Materials and methods

The first 18 gallstones patients operated in the Pediatric Surgery Department of the Clinical Emergency Hospital for Children "Louis Turcanu" Timisoara – Romania were analyzed durring January 2013 – September 30th 2015. Data was collected on age, weight, gender, Body Mass Index (BMI), comorbidities, time of surgery, number of ports used, using of drain and antibiotics and mean postoperative stay.

Results

The study included 14 females and 4 male patients with age ranging from 2-17 years (mean 12.7). Most frequently affected were those between: ages 10 to 16 (figure 1).

The weight of the patients ranged between 12-73 kg (mean 49.9) with BMI ranging between 16.8-28.2 (mean 21.3) (figure 2). We found that 2 patients were underweight, 13 were normal weight, 3 being overweight, however obesity and morbid obesity was absent in this cohort.

[1,2]University of Medicine and Pharmacy "Victor Babes" Timisoara – Department of Pediatric Surgery, Timisoara, Romania
[1,2]Clinical Emergency Hospital for Children "Louis Turcanu", Department of Pediatric Surgery, Timisoara, Romania
E-mail: radueiacob@umft.ro, mcpopoiu@yahoo.com, david.vlad@yahoo.com, vasilie_alex@yahoo.com, stanciulescucorina@yahoo.com, stretcu_lavinia@yahoo.com, alexnyiredi@gmail.com, boiaeugen@yahoo.com

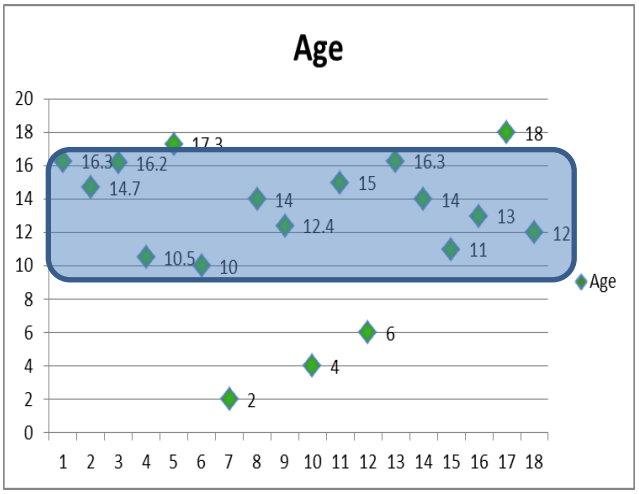

Figure 1. Case distribution according age.

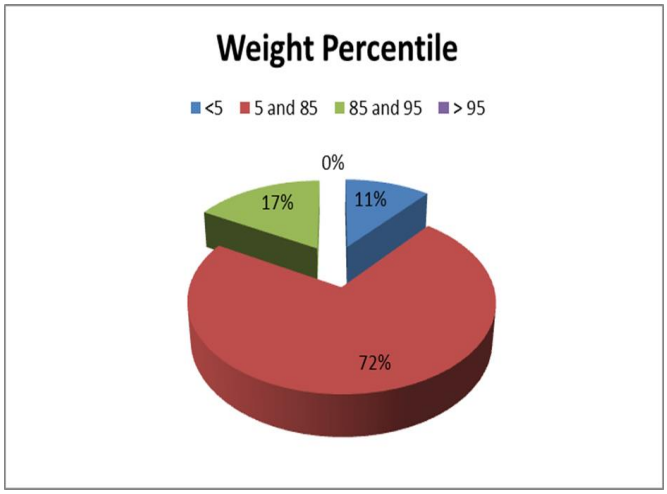

Figure 2. Case distribution according weight.

Discussions

Our study has shown a clear predominance of the female sex compared to males (14:4) unlike other similar studies published where there were 14 females to 10 males[3]. Immediate post-operative evolution by Espinosa-Saavedra D which found a 66.7 % female predominance[4] and another study in which the ratio was 8 males to 10 females.[5] However one recent study, published by Kim, mentioned a similar obvious predominance of the female sex,[6] similar to our findings.

The age ranged from ages 2-18 with a mean of 12.3, similar to those in the literature. [4,6]

The weight of the patients range from 12 kg-71 kg with a mean of 49.9 kg. The Body Mass Index or BMI ranged from 16.8-28.2 with a mean of 21.3. Most of our patients had normal bodyweight with no obese patients. 17% (3 patients) of the patients were overweight.

In our clinic we used 3 and 4 port technique for laparoscopic cholecystectomy. The latest trend is the single incision or single port cholecystectomy in children. Durring the last 5 years several centers have used this technique with similar results, comparable to the 3 or 4 port techniques. An article published in Am Surg. 2015 Sep by Farach SM et all. has done a retrospective review of 151 patients who underwent this procedure between 2009-2013 and have seen a decrease in operative time, only had 5 conversions, concluding that SILC can be safely introduced into a pediatric surgical practice.[7] A team of doctors in Africa found a new alternative to the SIPES in developing countries which performed the single-port surgery in children using an improvised trans-umbilical glove-port with conventional rigid instruments. They used a homemade trans-umbilical port consisted on: A flexible ring, a rigid larger ring, one powder-free surgical glove, a wire-to-skin and standard standards laparoscopic trocars. They found it is feasible, safe and effective. It may be an alternative to the costly commercially available single-port systems especially in a developing country.[8] Another team has been using single incision technique for the past 5 years published recently, who described the technique as safe with a complication rate of 6% concluding that operative times and complication rates are comparable to those in prior reported multiport laparoscopic series, allowing safe integration of SIPES into the routine of a surgical practice for most common procedures.[9] Despite SILS is a more challenging technique to perform, it is a safe and feasible alternative for cholecystectomy in children as all studies reviewed conclude.[10]

The duration of the surgical intervention varied between 60-165 min with a mean of 105 min. A study published in 2014 by a Spanish compared 39 children to 40 adults who underwent laparoscopic cholecystectomy. The mean operating time was significantly higher among children (127 min, adults 71 min, $p < 0.01$) but there were no differences neither in conversion nor in complication rates (children 5% and 7.7%, adults 2.5% and 15% respectively).[11]

All of the patients in our lot, except one, had drainage and antibiotics, mostly prophylactically.

The mean number of postop days was 4.41 for our patients. However the trend is for same day discharge as mentioned by Dalton et all. They conclude that same day discharge appears safe for pediatric patients undergoing laparoscopic cholecystectomy. The main obstacles to discharge were time of surgery completion and clinical care habits.[12] Zeidan et all published a paper in 2014 in which the median postoperative hospital stay was 1 day, concluding that in the study they conducted laparoscopic cholecystectomy in the pediatric population resulted in short postoperative hospital stay and had low complication rates. In particular, zero bile duct injuries were noted.[13] Another paper states that day case laparoscopic cholecystectomy is feasible and safe for children. Emphasis on adequate pain management and avoidance of postoperative nausea and vomiting results in a high rate of day case surgery equivalent to that achieved in adult practice.[14]

We had almost no complications during surgery, except for one case that required conversion

Espinosa-Saavedra et all. mentions that biliary lithiasis is a disease that is rarely diagnosed in children; in Mexico, its prevalence is less than 1 %, it occurs more frequently in adolescent females, hemolytic causes are rare and in most cases no cause was identified. More epidemiological studies are needed in order to understand the natural history of the disease in children.[15]

Conclusions

Interestingly in our cohort obesity did not play a role in gallstones. Most of our patients didn't present comorbidities. We had almost no complications during surgery, except for one case which required conversion due to bleeding and technical difficulties. In our clinic laparoscopic cholecystectomy is gold standard treatment for gall stones and biliary dyskinesia. More epidemiological studies are needed in order to better understand gallbladder disease in children. Despite SILS is a more challenging technique to perform, it is a safe and feasible alternative for cholecystectomy in children. Day case laparoscopic cholecystectomy is feasible and safe for children. Emphasis on adequate pain management and avoidance of postoperative nausea and vomiting should be considered.

References

1. Ashcraft's pediatric surgery © 2014, Elsevier Inc. All rights reserved., page 559-603.
2. Srinath A, Saps M, Bielefeldt K. Biliary dyskinesia in pediatrics. Pediatr Ann. 2014 Apr; 43(4)
3. Cofini M, Favoriti P, Pietrantoni S, Quadrozzi F. Management of pediatric cholelitiasis: our experience. Minerva Pediatr. 2014 Aug;66(4):267-73.
4. Espinosa-Saavedra D, Flores-Calderón J, González-Ortiz B, Rodríguez-González P.Characteristics of pediatric patients with biliary lithiasis. Immediate post-operative evolution.Rev Med Inst Mex Seguro Soc. 2014;52 Suppl 2:S74-7.
5. Gowda DJ, Agarwal P, Bagdi R, Subramanian B, Kumar M, Ramasundaram M, Paramasamy B, Khanday ZS. Laparoscopic cholecystectomy for cholelithiasis in children. J Indian Assoc Pediatr Surg 2009;14:204-6
6. Kim HY1, Kim SH1, Cho YH1. Pediatric Cholecystectomy: Clinical Significance of Cases Unrelated to Hematologic Disorders. Pediatr Gastroenterol Hepatol Nutr. 2015 Jun;18(2):115-20.
7. Farach SM, Danielson PD, Amankwah EK, Chandler NM.Impact of Experience on Quality Outcomes in Single-incision Cholecystectomy in Children. Am Surg. 2015 Sep;81(9):839-43.
8. Mahdi BD, Rahma C1, Mohamed J, Riadh M. Single-port laparoscopic surgery in children: A new alternative in developing countries. Afr J Paediatr Surg. 2015 Apr-Jun;12(2):122-5.
9. Seims AD1, Nice TR, Mortellaro VE, Lacher M, Ba'Ath ME, Anderson SA, Beierle EA, Martin CA, Rogers DA, Harmon CM, Chen MK, Russell RT. Routine utilization of single-incision pediatric endosurgery (SIPES): a 5-year institutional experience. J Laparoendosc Adv Surg Tech A. 2015 Mar;25(3):252-5.
10. Chrestiana D, Sucandy I. Current state of single-port laparoscopic cholecystectomy in children Am Surg. 2013 Sep;79(9):897-8.
11. Simal Badiolal I, Corona Bellostas C, Sagarra Cebolla E, Velasco Sánchez E, Zornoza Moreno M, Rojo Díez R, Pérez Egido L, Cerdá Berrocal JA, García-Casillas Sánchez MA, Peláez Matal D, Fanjul Gómez M, Molina Hernando E. Laparoscopic cholecystectomy: what we can learn about. Cir Pediatr. 2014 Oct;27(4):165-8.
12. Dalton BG, Gonzalez KW, Knott EM, St Peter SD, Aguayo P. Same day discharge after laparoscopic cholecystectomy in children. J Surg Res. 2015 May 15;195(2):418-21.
13. Zeidan MM1, Pandian TK, Ibrahim KA, Moir CR, Ishitani MB, Zarroug AE. Laparoscopic cholecystectomy in the pediatric population: a single-center experience. Surg Laparosc Endosc Percutan Tech. 2014 Jun;24(3):248-50.
14. Agarwal P, Bagdi RK. Day case laparoscopic cholecystectomy in children: A review of 11 cases. J Indian Assoc Pediatr Surg. 2014 Apr;19(2):61-4.
15. Espinosa-Saavedra D1, Flores-Calderón J, González-Ortiz B, Rodríguez-González P. Characteristics of pediatric patients with biliary lithiasis. Immediate post-operative evolution. Rev Med Inst Mex Seguro Soc. 2014;52 Suppl 2:S74-7.

Correspondence to:

Popoiu Călin Marius
Department of Pediatric Surgery,
University of Medicine and Pharmacy
"Victor Babes" Timisoara,
Eftimie Murgu, 2,
Timisoara
Romania
E-mail: mcpopoiu@yahoo.com

ADRENOGENITAL SYNDROME: POSITIVE DIAGNOSIS, EVOLUTION AND PROGNOSIS

Mariana Boia[1], Aniko Manea[1], Nicoleta Mutica[2], Ioana Micle[2], Otilia Marginean[3]

Abstract

The adrenogenital syndrom is a group of autosomal recessive diseases which causes the disturbance of the synthesis of suprarenal corticoids.

We present the case of a newborn, age 2 days, female, born prematurely, gestational age 36 weeks, with a malformation of the external genitalia, which shows at age of 1 week deterioration of general condition, loss of appetite, weight loss, severe dehydration syndrome, hyponatremia, hyperkalemia. We suspected the adrenogenital syndrome, which was later confirmed. With a specific treatment the evolution was favorable.

Key words: adrenogenital syndrom, newborn

Introduction

Congenital adrenal hyperplasia or adrenogenital syndrome is a group of autosomal recessive disorder caused by deficiency of one or more enzymes involved in normal synthesis of steroids (aldosterone, cortisol and sex hormones) .In all forms there is decreased production of cortisol leading to an increased synthesis of pituitary ACTH, resulting in excessive adrenal stimulation with its hyperplasia, associated with hypersecretion of steroids and their metabolites.(1)

The most common cause of congenital adrenal hyperplasia (90-95% of cases) is the result of a deficiency of 21-hydroxylase. Depending on the clinical manifestations, adrenogenital syndrome can be divided into a classic tipe, with neonatal onset, which is divided into variant associated with salt-waste, and without salt -waste (simple virilizing variant), and anon-classical tipe, with late-onset.

The classic tipe of adrenogenital syndrome has an incidence of 1 in 15,000 to 20,000 births of live fetuses. About 75% of infants affected associates aldosterone deficiency which causes loss of salt (Debra and Fibiger described formin newborn and infant),associated with cerebriform adrenal hyperplasia ,withthe masculinization of external genitalia in girls. Clinical symptoms occur during the first 2 weeks of life: hyponatremia, hyperkalemia, blood volume depletion, hypotension, hypotonia, psychomotor agitation, stationary or declining growth rate, and acute dehydration syndrome in severe forms.Non-classical tipe occurs in childhood or young adulthood with hirsutism, amenorrhea and infertility, and has an incidence of 1 in 1,000 births of live fetuses. (2,3)

Description of case

Newborn, aged 2 days, coming from monitored pregnancy, GII PII, birth by caesarean section, premature ruptured membranes, gestational age 36 weeks, birth weight 2480g, 47cm waist, with satisfactory early neonatal adaptation, IA = 8 / 1', mother with negative Rh without antibody titer, at clinical examination are seen a malformed genitalia (clitoris hypertrophy) and suspected a malformation of the urinary tract (urine passing through the vagina).

The clinical status at admission is relatively good, balanced cardio-pulmonary, renal lodges free diuresis present, urine passing through the vagina; external genital organs - hypertrophy of the clitoris, labia majora pseudoscrotal looking.

In evolution, at age of 1 week, the overall condition of the newborn deteriorates, with drowsiness ,inability of feeding, weight loss. ASTRUP index reveals hyponatremia (sodium minimum values of 118,7mmol / l) and hyperkalemia (potassium maximum values 7,3mmol / l). (tab.1)

It raises the suspicion of adrenogenital syndrome and completed the laboratory investigations.

Genetic exam: ambiguous appearance of external genitals, intersexual stage Prader III, normal female karyotype: 46 XX

Abdominal and pelvic ultrasonography: liver without expansion of intra and extra hepatic biliary, normal size; currently gallbladder; normal spleen size; kidneys with echogenic and normal size; full bladder; uterus and vagina viewable ultrasound (fig. 1), ultrasound undetectable ovaries; bilateral adrenal glands hypertrophy (fig.2,3). Conclusion: Bilateral congenital adrenal hyperplasia.

Transfontanelar ultrasonography: interhemispheric fissure normally, lateral ventricles 2mm, V3-V4 normally, normal brain tissue, periventricular formations at the base of the lateral ventricles bilateral.Conclusion: bilateral subependymal hemorrhage.

[1]University of Medicine and Pharmacology ‘’Victor Babes’’, Neonatology, Timisoara, Romania
[2]Emergency Children Hospital “Louis Turcanu”, Neonatology, Timisoara, Romania
[3]University of Medicine and Pharmacology “Victor Babes”, Pediatric Clinic, Timisoara, Romania
E-mail: marianaboia@yahoo.com, aniko1807989@yahoo.com, nicoletadelina@gmail.com, omarginean@ymail.com

Tab.1 -laboratory investigations at admission.

17-α-hidroxiprogesteron (VN< 8,000)	33,670ng/ml
Androstendion (VN=0,2000-1,1000)	>10,000 ng/ml
Cortizol (VN=171-536)	307,1 nmol/L
Estradiol	50,4pg/ml
LH	<0,100mUI/ml
Progesteron	39,95ng/ml
Testosteron (VN=75-400 μg/dl)	6,00 ng/ml
TSH (VN=0,43-16,1)	1,36 pUI/ml
FT3 (VN=3,08-8,1)	5,09 pmol/l
FT4 (VN=10,6-39,8)	18,5 pmol/l

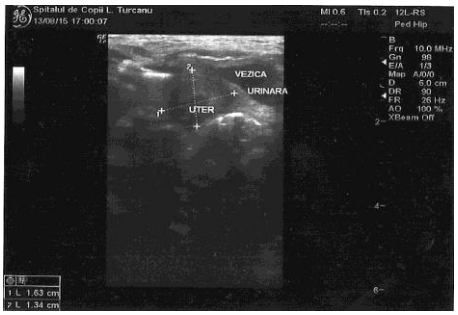

Fig. 1 Ultrasonograhyc appearance – uterus.

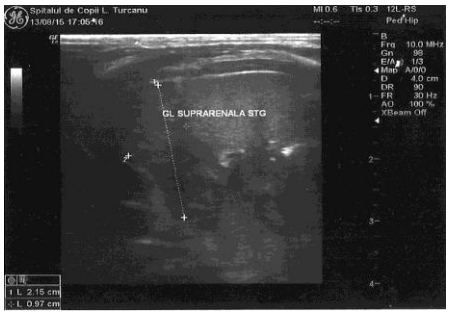

Fig. 2 Ultrasonograhyc appearance – left adrenal gland.

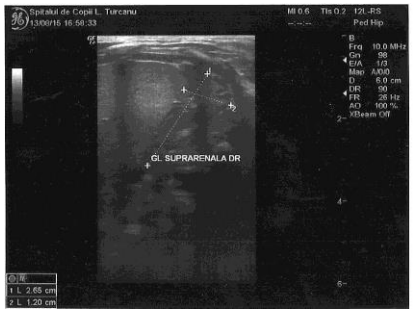

Fig. 3 Ultrasonograhyc appearance – right adrenal gland.

Pediatric endocrinologic exam: hypertrophy of the clitoris, labia majora pseudoscrotal looking intersexual Prader-stage III / IV; it's recommended to start Astonin and Hydrocortisone treatement.

We start *the treatment* with Astonin (fludrocortisone) 0.05 mg / day; initial hemisuccinat corticosteroid hydrocortisone intravenously with 10mg / kg / day in 4 doses, then oral Hydrocortisone 20mg / m2 in 3 doses; rebalancing hydroelectrolytic infusion (with additional sodium) and acid-base status. The sodium in the diet was supplemented.

Under treatment, the general state gradually improved, with normalization of sodium, potassium and hormonal values.

Discussions

Although the prognosis is good with proper treatment, however, the infant mortality rate of newborns with congenital adrenal hypertrophy undetected through neonatal screening is 11.9%.

Most often under diagnosed or late diagnosed cases are those of the males, which presents more discreet virilising signs than women. However we can not make a parallel between the degree of virilization of the external genitalia and severity of the disease in women. It can meet the appearance of female pseudohermaphroditism, where there is a structure and normal position of internal genitalia, and external genital abnormality that can be quantified as Prader's scheme. Female pseudohermaphroditism of 21-hydroxylase deficiency is the most common leading cause of intersex newborn.

Among infants affected by 21-hydroxylase deficiency, approximately 75% present the salt-waste tipe of the disease. This occurs about 2 weeks old, later to the breastfed infants and earlier ato the premature babies.

At the time of occurrence of salt-waste syndrome the diagnosis is facilitated, but treatment is urgent need to establish, in its absence the circulatory collapse, shock and death occur inevitable. In some cases of congenital adrenal hypertrophy there are brain damage caused by shock, and distance learning and cognitivedifficulties.(4,5) To the male newborns salt – waste occurs much later and adreno-genital syndrome diagnosis often is not done in the first year of lifeAt the time salt-waste apears, most likely it is a congenital adrenal hypertrophy.

In the absence of neonatal screening and without a family history of the disease, all male infants and a small percentage of the female remain undiagnosed until adrenal crisis. In many countries began the screening of newborns between day 3-5 of life by measurement of 17-OH progesterone in capillary blood and antenatal screening by chorionic villi or amniotic fluid molecular genetic testing.

All patients diagnosed with adreno-genital syndrome requires treatment with glucocorticoids for the correction of existing cortisol deficiency: hydrocortisone oral dose of 20 mg / m2 / day in two or three doses.Subjects with salt-waste requires replacement with mineralocorticoids: fluorohidrocortisone 0.1-0.2 mg / day, to normalize the balance of sodium / potassium,and in acute crises of salt-waste is used maximum dose of hydrocortisone intravenously, and sodium supplementation in rebalancing hydroelectrolytic infusions.(6,4)

Once with the ageing the salt-waste syndrome attenuates,treatment is required only in decompensation moments outcome in mistakes in drug therapy, during intercurrent diseases, traumas, intoxications.Whitout proper treatment it can cause short stature because of the early welding of the growth cartilage at the age of 7-8 years, particular phenotype, virilizations, early puberty, cognitive deficits.With a proper treatment the pacients can reach a normal stature, with a psihointelectual evolution and a normal reproductive capacity.Treatment efficiency can be verified by periodic dosing of the 17-hidroxiprogesterone, androstenedione and testosterone, by the rithm of the growth, bone age,blood pressure in salt-waste type.(4)

Female patients with external genitals abnormality can have a reconstructive surgery.

Psychotherapy is necessary for a better understanding of the disease, chronic treatment, so there is a better evolution of the disease

Prophylactic treatment consists in administering dexamethasone 20 mg / kg in 2-3 intakes at-risk pregnant women in the first 6 weeks of pregnancy.It prevents virilization and sexual ambiguity to the female fetus, but the chronic substitution treatment to the affected child will still be necessary.(7,2)

Conclusions:

• positive diagnosis is relatively easy to determine when external genitalia are modified and salt-waste syndrome occurs

• onset diseases is more quickly (in the first week of life) in premature born compared with term born baby

• for positive diagnosis requires a multidisciplinary team (pediatrician, endocrinologist, geneticist)

• Long-term evolution of the case depends on the rigor with which treatment is administered, and adjust it according to biological and hormonal investigations

• a good parents education in understanding disease, chronic treatment and need periodic investigations is very important

References

1. Thomas Green, Wayne Franklin, Robert R. Tanz, Congenital Adrenal Hyperplasia, Pediatrics, Just the Facts, 2002.
2. Merke DP. Approach to the adult with congenital adrenal hyperplasia due to 21-hydroxylase deficiency. J Clin Endocrinol Metab. 2008.
3. Speiser PW, Azziz R, Baskin LS, Ghizzoni L, Hensle TW, Merke DP. Congenital adrenal hyperplasia due to steroid 21-hydroxylase deficiency: an Endocrine Society clinical practice guideline. J Clin Endocrinol Metab. 2010
4. Robert M. Kligeman, MD Bonita, MD Stanton, Perrin C. White et all, Nelson, Textbook of Pediatrics, 19th Edition, Congenital Adrenal Hyperplasia and Related Disorders, 570.1,1930-1934, Ed. Saunders, 2011.
5. Joint LWPES/ESPE CAH Working Group. Consensus statement on 21-hydroxylase deficiency from the Lawson Wilkins Pediatric Endocrine Society and the European Society for Paediatric Endocrinology. J Clin Endocrinol Metab. 2002
6. Rudolph Colin D., Mechanism of hormone action, Rudolph's Pediatrics, 21-st Edition, 24-1, 2004-2011,2002.
7. Hirvikoski T., Nordenström A., Wedell A., Ritzén M., Lajic S. – Prenatal dexamethasone treatment of children at risk for congenital adrenal hyperplasia: the Swedish experience and standpoint, J Clin Endocrinol Metab. 2012

Correspondence to:

Otilia Marginean
"Victor Babes" University of Medicine and Pharmacy,
Department of Pediatrics
2 Eftimie Murgu 300041
Timisoara, Romania
E-mail: omarginean@ymail.com

ABNORMAL UTERINE BLEEDING IN ADOLESCENT FEMALES

Marius Gliga[1], Camelia Gliga[2], Maximilian Gliga[3]

Abstract

Abnormal uterine bleeding is a possibly severe condition which apears in the first years of reproductive activity. The etiology is very complex, with anovulation being the most frequent cause. The diagnosis is difficult and has to be very thorough and quick. The therapy must commence during the diagnosis and must be in relationship with the etiology, with the severity of the case and sometimes requires interdisciplinary work.

Key words: abnormal uterine bleeding, adolescence, hormonal treatment

Introduction

Abnormal uterine bleeding, which is heavy, prolonged or frequent bleeding of uterine origin causing various degrees of anemia, is a condition that appears relative often in adolescence, being sometimes a very severe disease even a life threatening condition. In the first years after the menarche the menstrual cycle is carachterized by a high grade of irregularity. This is due to the immaturity of the hylothalamus-hypophyse axis and its instable connections with the ovaries. So most of the cycles in this period are anovulatory – monophasic. In the anovulatory cycles the progesterone secretion in the second part of the cycle (the luteal phase) is lacking. Without progesterone the endometrium is only under estrogene influence. Even if the estrogen level is not elevated, being sometimes at the level of the mid folicurar phase or even lower, the stimulation of the endometrium by the sole estrogens causes a hyperprolipheration. Being under estrogen stimulation a longer period of time, the endometrium overgrowths its blood supply and so parts of it shedd from the uterine wall. This causes bleeding from those portions of the uterine cavity. The healing of the desquamated parts of the endometrial cavity will be irregular as is the shedding. When some parts of the endometrium are healed other parts are sloughing. The bleeding was compared with a chess board. The bleeding is also favoured by the weak contractility of the insufficient developed uterus.In the first 2 years after the menarche only 7-8% of the cycles are ovulatory, this proportion rising to 40% in the next 2 years. Therefore it can be stated that in this period of the female life there is a relative functional infertility.

The menstrual bleeding is pathologic if the amound of blood loss is over 80mL or if it lasts more then 7 days.

The excesive menstrual bleeding can be the first symptom of a hemathologic disease.

Diagnosis – anamnesis

Establishing a good communication with the patient is very important but sometimes also difficult. In collecting a good history of the disease the phisician must speak with the adult part of the patient`s family and be carefull of the fact that the young girl can hide some parts of the history because of her parents being there. The doctor must carrefully interogate the patient and the family and sometimes, being very cautios, must speak with the young girl alone and try to win her confidence. A good psychologic background of the gynecologist is of great advantage.

For the therapy of the bleeding we must exclude the organic causes of bleeding. One of the alghorithms of etiologic diagnostic of the bleeding is the PALM - COEIN classification, P - polyps (endometrial), A - adenomyosis, L- leiomioma, M – malignancy and hyperplasia, theese being the structural causes and C – coagulophaty, O – ovulatory disorders, E – endometrial, I – iatrogenic, N – not classified. But this classification is for women in reproductive age and for adolescetnts needs some adjustments. Practicaly, adenomyosis and leiomioma don`t appear in adolescents. Polyps and malignancy are very seldom - one case of endometrial polyp at a 13 year old girl [1] and one case of endometrial cancer at a 15-year old girl found in the literature [2]. So we must concentrate in the second part of the classification, most of the cases being due to the ovulatory disorders. At this subject the diagnosis must go further in revealing endocrine pathology as a cause of the ovulatory disfunction or the cause of the anovulation being the immaturity of the nervous-endocrine-genital system.

One of the traps in the management is the exageration of the symptoms in some cases and the slighting of the clinical signs in other cases. We encountered both in our practice.

The second one is more dangerous because can lead to a late presentation at the gynecologist with all the possible complications even life threatening. This is also the result of insufficient information about the menstrual cycle between adolescents [3].

[1]Clinic of Obstetrics and Gynecology II Targu Mures,
[2]Clinic of Endocrinology Targu Mures,
[3]Student of University of Medicine and Pharmacy Targu Mures,
E-mail: m11gliga@yahoo.com, gliga.camelia@gmail.com, maxtenn111@yahoo.com

The history must reveal the age of the onset of the menses, how were the first cycles (frequency, duration, intensity, regularity of the menses).

Then we must seek symptoms of coagulopathies (von Willebrand disease, idiopathic thrombocytopenia, leukemia). History of coagulopathies in the family must be carefully interogated. Furthermore the patient is asked about heavy bleeding by little wounds, epistaxis, slight bruising, purpura or petechiae. Sometimes the abnormal uterine bleeding is the first symtome of the existing coagulophaty [4]. Also, one fifth of the adolescent with heavy uterine bleeding have been found to have a coagulopathy [3].

It is important to try to reveal anathomic causes of the bleeding, like visible abdominal masses and the sexual history of the pacient, a most delicate issue.

Next, the pacient and the family are questioned about medication used in the last period, like contraceptives, anticoagulants, aspirin and other nonsteroidal antiinphlamatory drugs.

Also the history must continue with the search of symptoms of eat disorders, symptoms of PCOS, thyroid diseases, diabetes, hyperprolactimenia, hepathic diseases, renal failure, neurologic diseases (10-24% of girls with epilepsy have PCOS and by girls with valproic acid treatment 40% have PCOS and 30% menstrual disorders), reumatologic diseases (chronic juvenile arthritis, lupus), gastrointestinal diseases (inflammatory) and cianotic cardiac diseases [5].

The history will be completed with the actual disease, by reviewing the last normal menstruation, the onset of the actual bleeding and its evolution – the intensity of the bleeding is sometimes difficult to evaluate by the patient or the parents. Our opinion is that scores like the pictorial bleeding assessment calendar (PBAC) are not very usefull especially in emergency situations. The use of more than 8 pads in 24 hours or change of the pad more often than hourly or clots larger than 3 cm signify an abnormal menstrual bleeding [6].

Even if we are dealing with a very young patient, we must not forget to ask about normal and complicated pregnancy symptoms, like nauseea, breast tendeness, pelvic pain or discharge of soft tissue through the vagina. It is very possible that young patients will hide or deny theese symptoms if the parents are there.

Diagnosis – physical examination

The examination of the patient beginns with the inspection of the skin, revealing palour (sign of anemia), petechiae (sign of coagulopathy), or hirsutism (sign of hyperandrogenic disorders including PCOS). Next the blood pressure, pulse, temperature, weight and height are measured, and BMI is calculated.

Briefly we must palpate the thyroid and the breasts. Then an abdominal palpation is carefully done focusing on abdominal or pelvic masses (one must remember that ovarian cysts and benign or malignant tumors are possible even at this age). Hepatomegaly or splenomegaly must also be excluded.

Then it comes to the difficult issue of pelvine examination. This is possible in non virgin adolescents, with a speculum examination and digital palpation through the vagina. The source of the bleeding is clarified, the intensity of the actual bleeding is evaluated, enlarged uterus, signs of pelvic inflamatory disease or parauterine tumors are being diagnosed. Attention to foreign bodies, injuries of the vulva, vagina or hymenal ring. By virgin girls the examination will be the inspection of outer genitals and eventually rectal examination (we didn`t use it).

Diagnosis – laboratory

Start with a complete blood count, fibrinogen, coagulation time, prothrombin time, partial thromboplastin timeand blood type. By non virgin girls, pregnancy test is mandatory. During the speculum examination the gynecologist must take probes for cultures and Chlamydia trachomatis (DNA probes are prefered if available). Depending on the hystory of the patient other analysis are required: TSH, fT4, prolactin, dehydroepiandrosterone sulphate, testosterone, 17-hydroxyprogesterone, von Willebrand factor antigen, risocetin C cofactor, factor VIII, glucose and glucose tolerance test.

Diagnosis – ultrasound examination

The best examination is the transvaginal ultrasound. Because it is not possible in all cases (by virgin girls), we are obliged to examine the girls transabdominaly. If we do so then the examination is better with full bladder. The ultrasound examination is very valuable in excluding organic causes of uterine bleeding, like pregnancy complications, uterine fybroids, endometrial polyps, endometrial cancer, ovarian cysts, ovarial benign or malignant tumors. Also through ultrasound polycystic ovarian syndrome is identified (together with specific hystory and laboratory findings). Ultrasound is also very important in evaluating the endometrium, with consequences in the therapy. A thick endometrium is the sign of a hyperproliferation through relativ hyperestrogenemia or intrauterine clots. A thin endometrium indicates a hypoestrogenemia.

Therapy

The therapy must begin during the diagnostic procedures. We must obtain quickly intravenous access and administrate crystalloids, the volume depending on the gravity of the anemia (tachicardy, palour, orthostatic hypotension). When a gynecologist has to handle such a case, he must always think that a youg organism is a system with a lower stability, so sometimes quick intervention is required. After the first results of the emergency complete blood count, in colaboration with the intensive therapy unit, we decide and administer blood products. This is the case when hemoglobin is under 7 g/dL or in symptomatic severe anemia or shock.

Another principle of treatment is avoiding surgical procedures or perform a minimum invasiv one. Of course the decision of a surgical procedure is very difficult at a virgin young girl where preservation of the himenal ring in

some families is important and the preservation of the fertility is always a very important issue.

If the organic, systemic, endocrine and hemathologic causes are excluded then the hormonal therapy is initiated. In our opinion, the therapy must be guided after the results of the ultrasound examination of the endometrium.

By cases with thick endometrium we prefer the oral combined contraceptive pill with 30 mcg ethinyl estradiol, 1 pill every 6 hours until the bleeding stops, then, after one day, 3 pills daily 3 days, then 2 pills daily 3 days and finally 1 pill in 24 hours for 10-15 days. In our experience pills with 30 mcg ethinyl estradiol and dienogest as a progestative was very good in acute cases and also for long term therapy in preventing reccurent menorhagia. Unfortunately this pill is out of the market in Romania. The good efficacy of dienogest containing tablets was also studied by other authors which found that it was highly effective- the combination was with estradiol valerate, not with ethinylestradiol as in the pill we used [7]. Actually this combination of estradiol valerate and dienogest (Natazia) is the only one approved by the FDA for the treatment of heavy menstrual bleeding [8].

As an alternative, we can use injectable progesterone 100-200 mg intramuscular, then oral therapy with 200 – 400 mg micronized progesterone daily for 10-14 days. Another progesterone acute therapy is the administration of norethisterone 10 mg three times a day [9]. Another progesterone only therapy, whose efficacy havs been demonstrated in a well conducted study is the administration of 150 mg depo-medroxyprogesterone acetate intramuscular, followed by the oral administration of 20 mg medroxyprogesterone acetate every 8 hours for three days. But the study was not for adolescents only and hemodynamically unstable patients and those with hemoglobin less then 8 g/dL were excluded [10]. So, the treatment can be very good in moderate form of uterine bleedings.

By cases with thin endometrium we use the same scheme with oral combined contraceptive (4, 3, 2, 1) or Premarin 25 mg intravenous every 4 - 6 hours for maximum 24 hours, then a combination of oral contraceptives or progesterone only, 10 – 14 days. The bleeding usually ceases with this therapy during the first day. If not, reevaluation is needed.

When we use a treatment with estrogen containing products we must take care of the contraindications to estrogen, like lupus erytematosus, personal or close family history of venous thromboembolism – how important is a good anamnesis! – and in those cases we use therapies with progestin-containing products [9].

As a associated therapy, we used injectable ergomethrin or misoprostol orally. As an uterotonic is used also oral antiprogesterone. Also, nausea being a frequent secondary effect of the estrogene therapy, we use antiemethics. And by prolonged bleeding, especially when there is a liquid in pelvis (identified at ultrasound) we recommend antibiotics.

Antifibrinolytic drugs, like tranexamic acid or aminocaproic acid, have been used in the treatment of menorhagia alone or in combination with a non-steroidal-antiinflamatory drug or with hormonal therapy [11]. They are indicated especially at patients with bleeding disorders, interdisciplinary aproach (with the hematology unit) being necessary. We have no experience with these treatments, anyway this drugs have been removed from the market in Romania.

Desmopressin is indicated for the treatment of uterine bleeding in patients with von Willebrand disease. In such cases we recommend collaboration with a hematologist.

The levonorgestrel intrauterine device was also used as a therapy for bleeding in adolescents [12], but is a difficult decision in virgin girls and in non virgin but nuliparous adolescents there is the possible late complication of infertility. We have not used this therapy.

Other treatments in patients with coagulopathies are platelet transfusions, factors 7, 8, 9, 10, 13, fibrinogen, fresh frozen plasma, cryoprecipitate or prothrombin complex concentrates. These are reserved only at patients where the coagulopathy has been investigated and only in consultation with a hematologist [13].

Exceptional therapies, used only in very severe cases which do not respond to medical therapy and there is a life threatening condition, are: vaginal examination under general anesthesia and evacuation of the intrauterine clots, dilatation and curetage, histeroscopy, Foley catheter intrauterine, uterine artery embolisation, endometrium ablation and hysterectomy. Fortunately, in our activity we have not been obliged to use such therapies.

From these treatmens we would choose the intrauterine insertion of a Foley catheter with the help of a rigid instrument fittet into the tip of the catheter, after a small dilatation of the cervix [14].

In conclusion we state that abnormal uterine bleeding in adolescent girls is a condition with possible severe complications, which requires a rapid but thorough diagnosis and a quick, exact and sometimes curageous therapy.

References

1. Noorhasan D, Weiss G: Endometrial Polyp as a cause of dysfunctional uterine bleeding in adolescence, NASPAG 22-nd Annual Clinical Meeting, doi:10.1016/j.jpag.2008.01.027.
2. Elnaggar AC, Spunt SL, Smith W, Depas M, Santoso JT: Endometrial cancer in a 15-year-old girl: A complication of Cowden Syndrome, Gynecologic Oncology Reports 3, 2013, 18–19.
3. Adams Hillard PJ: Menstruation in Adolescents: What Do We Know? and What Do We Do with the Information?, J Pediatr Adolesc Gynecol 2014, 27, 309-319.

4. Seravalli V, Linari S, Peruzzi E, Dei M, Paladino E, Bruni V: Prevalence of Hemostatic Disorders in Adolescents with Abnormal Uterine Bleeding, J Pediatr Adolesc Gynecol, 2013, 26, 285-289.
5. LaCour DE, Long DN, Perlman SE: Dysfunctional Uterine Bleeding in Adolescent Females Associated with Endocrine Causes and Medical Conditions, J Pediatr Adolesc Gynecol, 2010, 23, 62-70.
6. Ahuja SP, Hertweck SP: Overview of Bleeding Disorders in Adolescent Females with Menorrhagia, J Pediatr Adolesc Gynecol 2010, 23, S15-S21.
7. Jensen JT, Parke S, Mellinger U, Machlitt A, Fraser IS: Effective treatment of heavy menstrual bleeding with estradiol valerate and dienogest: a randomized controlled trial, Obstet Gynecol, 2011, 117, 777-87.
8. Bradley LD, Gueye N-A: The medical management of abnormal uterine bleeding in reproductive-aged women, American Journal of Obstetrics & Gynecology 2015, in press
9. Michala L, Creighton S: Adolescent gynaecology, Obstetrics, Gynaecology and Reproductive Medicine, 2014, 24:3, 74-79.
10. Ammerman SR, Nelson AL: A new progestogen-only medical therapy for outpatient management of acute, abnormal uterine bleeding: a pilot study, American Journal of Obstetrics & Gynecology, June 2013, 499e1-499e5.
11. American College of Obstetricians and Gynecologists Committee on Adolescent Health Care: American College of Obstetricians and Gynecologists Committee Gynecologic Practice: ACOG Committee Opinion No. 451: Von Willebrand disease in women, Obstet Gynecol 2009; 114:1439
12. Chi C, Pollard D, Tuddenham EG, et al: Menorrhagia in adolescents with inherited bleeding disorders. J Pediatr Adolesc Gynecol 2010, 23, 215.
13. Venkateswaran L, Dietrich JE, Gynecologic Concerns in Pubertal Females with Blood Disorders, J Pediatr Adolesc Gynecol, 2013, 26, 80-85.
14. Wilkinson JP, Kadir RA: Management of Abnormal Uterine Bleeding in Adolescents, J Pediatr Adolesc Gynecol, 2010, 23, S22-S30.

Correspondence to:
Camelia Gliga
Spitalul Clinic Județean Targu Mures
Compartiment Endocrinologie
Str. Gheorghe Marinescu nr. 38
Email: gliga.camelia@gmail.com

DIET ANALYSIS IN OBESE CHILDREN

Raluca-Monica Pop[1], Ionela Pașcanu[2]

Abstract

Background: Childhood obesity is a public health issue and the available management options include dietary recommendations which are time-consuming and general. Diet analysis can help in improving the obesity treatment.

Aim: to evaluate the food pyramid and dietary patterns in obese children.

Material and methods: cross-sectional study on a sample of 82 children 5-19 years with abdominal obesity evaluated between March 2013 - April 2014 in the Emergency County Hospital Mures. Variables: age, sex, environment, BMI Z score (according to the WHO charts), food pyramid, diet composition. Each child was measured and weighted by the same person, using verified instruments. Each legal representative filled in a food frequency questionnaire regarding eating habits for the previous 6 months. The questionnaire has 126 items and for each one there are 10 frequencies to choose from. A dedicated web-based tool was developed for the questionnaire analysis which returns the personal food pyramid based on the questionnaire and allows further group analysis of dietary patterns, using different criteria, and variable number of food items.

Results: The mean age was 12.4±4.8 years, with a predominance of females (1.34:1) and of the urban environment (2.28:1). 64.6% of the subjects (n=53) were obese. Sex and the environment have no influence on the food pyramid, although children from rural areas have more unhealthy eating habits when analyzing diet composition. Age is significantly negatively correlated with all food groups' number of servings. Children at pubertal age have more healthy eating habits than younger ones.

Conclusion: Diet analysis is a useful tool in the management of overweight and obesity, but more objective methods for assessment must be developed.

Key words: childhood obesity, food pyramid

Introduction

Childhood obesity has become a major public health issue, the burden of the disease being very well demonstrated [1]. In children obesity is associated with a wide range of health complications and an increased risk of premature onset of illnesses, including diabetes and heart disease. Preventing childhood obesity is a key approach to the primary prevention of noncommunicable diseases.

The obesity epidemic has the potential to negate many of the health benefits that have contributed to the increased longevity observed in the world. The WHO's Commission on Ending Childhood Obesity has developed a report describing future policy directions with the aim of countering this epidemic [2].

The management of obesity focuses on lifestyle changes, including dietary recommendations. The latter are difficult to obtain given the subjective and time-consuming diet analysis.

Aim

To evaluate the food pyramid and dietary patterns in obese children.

Subjects and methods

A cross-sectional study was conducted between March 2013 and April 2014 in the Emergency Mures County Hospital involving children with abdominal obesity from 5-19 years of age. Sample: 82 children. Exclusion criteria: secondary causes of obesity, refusal to participate.

Variables: age, sex, environment, BMI Z score (according to the WHO charts), food pyramid, diet composition. Abdominal obesity was defined as waist above the 80th centile according to the curves developed by Fernandez et al. in 2004 [3]. Overweight was defined as 1SD < BMI < 2SD and obesity was defined as a BMI > +2 SDS according to the WHO reference. The ideal food pyramid was defined as follows: cereal at least 6 portions/day, fruits and vegetables, at least 5 portions, dairy 3 portions, meat 2 portions, fat 2 portions, concentrated sweets maximum 1 portion.

Method: each child was measured and weighted by the same person, using verified instruments. Each legal representative filled in a food frequency questionnaire regarding eating habits for the previous 6 months. The questionnaire has 126 items and for each one there are 10 frequencies to choose from. It was developed based on the one used in the 3rd NHANES and adapted to local food habits. A dedicated web-based tool was developed [4] for the questionnaire analysis which returns the personal food pyramid based on the questionnaire and allows further group analysis of dietary patterns, using different criteria, and variable number of food items.

[1]Research Methodology Department, UMF Tg Mures
[2]Endocrinology Department, UMF Tg Mures
E-mail: ralucapetri@yahoo.com, iopascanu@gmail.com

The study was approved by the local Ethics Committee and each legal representative had to sign an informed consent.

Statistical analysis: for data collection the M.O Excel and the web-based tool were used; for statistical analysis MedCalc v. 5.0 was used. Categorical and binary data were analyzed using the t-test, Mann-Whitney test, $\chi 2$ test for testing associations, Spearman or Pearson test for correlations. A level of significance α=0.05 was used.

Results

The mean age was 12.4±4.8 years, with a predominance of females (1.34:1) and of the urban environment (2.28:1). 64.6% of the subjects (n=53) were obese (table1).

Table 1 – General characteristics of the sample.

Variable	Girls	Boys	Total
n	47	35	82
Mean age (years)	12.5±4.9	12.2±4.9	12.4±4.8
Urban (n/%)	36 (76.6%)	21 (60%)	57 (69.5%)
Rural (n/%)	11 (23.4%)	14 (40%)	25 (30.5%)
Normal weight (n/%)	13 (27.6%)	8 (22.8%)	21 (25.6%)
Overweight (n/%)	5 (10.6%)	3 (8.5%)	8 (9.75%)
Obese (n/%)	29 (61.7%)	24 (68.57%)	53 (64.6%)

Considering the subjectivity of the food frequency questionnaire, we tested for outliers for each food group and eliminated them from the final analysis. The final sample was of 72 subjects. Both boys and girls eat more servings than the recommended amount, with significant differences for fruits and vegetables (figure 1). Environment has no significant influence on the food pyramid, but children from urban areas consume higher amounts of fruit and vegetable and lower amounts of cereal, sweets and fat.

When analyzing the food pyramid according to BMI, the only significant difference is in the fat amount, with obese subjects having the highest value. Overweight people consume the highest amount of food servings/day (figure 2).

Age is negatively associated with all the food groups, significant for sweets, fat, and dairy (table 2).

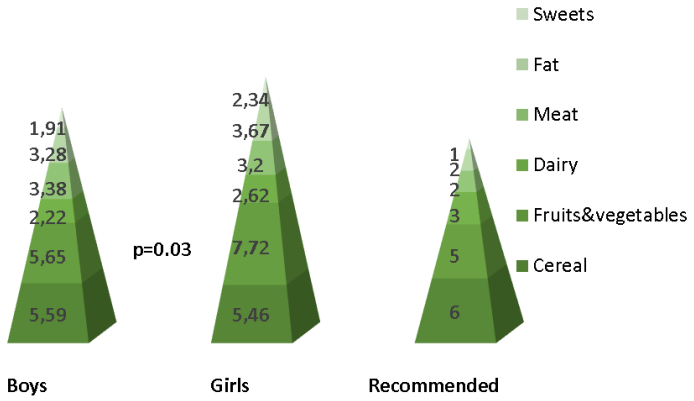

Figure 1 – The food pyramid of the subjects.

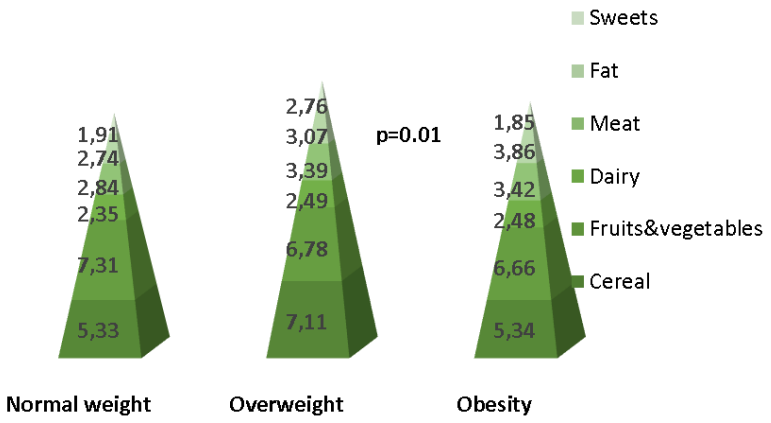

Figure 2 – The food pyramid depending on the weight.

Table 2 – Age correlation coefficients with the food groups.

Food group	r coefficient	95% CI	p
Sweets	-0.14	-0.23 – (-0.04)	0.003
Fat	-0.31	-0.51 – (-0.08)	0.007
Meat	-0.22	-0.43 – (-0.01)	0.06
Dairy	-0.27	-0.48 – (-0.04)	0.02
Fruits & vegetables	-0.22	-0.34 – 0.19	0.35
Cereal	-0.09	-0.32 – 0.11	0.45

Considering 12 years as the mean age for pubertal development and comparing the two groups, the younger the children, the higher the amount of fat and dairy consumed (figure 3).

When comparing the 2 groups regarding the first 3 items mostly consumed, the older children choose healthier fat and meat products, while consuming the exact same sweets and dairy.

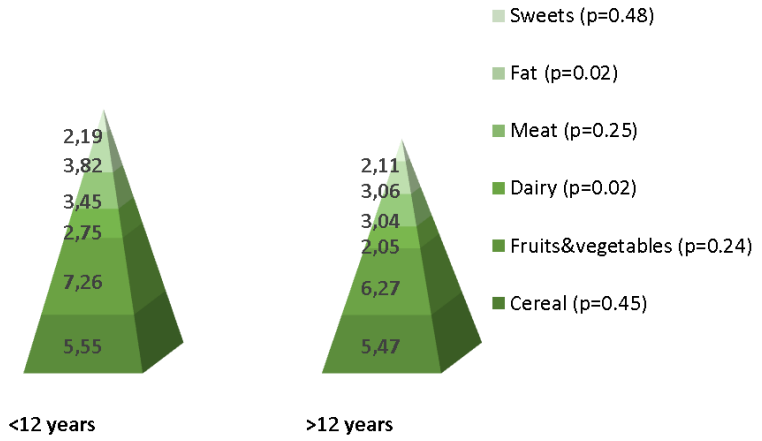

Figure 3 – The food pyramid depending on age.

Discussions

This study aimed to analyze the food pyramid and dietary patterns among obese children. Although diet analysis is time-consuming, it is an important part of the management of obesity, especially in children and adolescents. There are 2 meta-analysis that state the lack of consistency among studies regarding dietary interventions and the need for further well-designed populational studies in order to fully describe the diet's role in the management of obesity in children [5,6].

Diet assessment tools are available throughout the world-wide-web more or less controlled or based on guides or professional information. The high income countries have been using different types of assessment tools for developing national guidelines and recommendations [7].

Obese and overweighed children consume higher amounts of food servings than the current recommendations, with only small differences among sexes or environment, a result consistent with previous studies [8,9,10,11]. In our study, pubertal subjects had healthier food choices and consumed lower number of servings from all food groups. Other studies reported the opposite or no difference between prepubertal children and older ones [12,13]. This fact might be explained by the choice of 12 years as cut-off for pubertal development in our study.

Our results showed that age was negatively correlated with all food groups. Pre-pubertal children have a more controlled diet, compared with those in high school, directed by parents and school cafeteria food availability [14,15]. These results show the need for school policies that do not allow unhealthy foods to be available for children and public health policies that raise parents' awareness regarding the health burden of obesity [16].

We must state the limitations of our study: small sample, the subjectivity of dietary assessment, the lack of physical activity evaluation. Future populational studies are needed in order to fully understand the diet composition importance in childhood obesity.

Conclusion

Diet analysis is a useful tool in the management of overweight and obesity, but more objective methods for assessment must be developed.

References

1. Lobstein TJ-LR. Estimated burden of paediatric obesity and co-morbidities in Europe. Part 2. Numbers of children with indicators of obesity-related disease.. Int J Pediatr Obes. 2006;1(1):33-41.
2. WHO Commission on Ending Childhood Obesity. Draft Final Report of the Commission on Ending Childhood Obesity. Geneva: WHO; 2015. Available from: http://www.who.int/end-childhood-obesity/commission-ending-childhood-obesity-draft-final-report-en.pdf.
3. Fernández JR, Redden DT, Pietrobelli A, Allison DB. Waist circumference percentiles in nationally representative samples of African-American, European-American, and Mexican-American children and adolescents. J Pediatr. 2004;145(4):439-44.
4. Raluca-Monica POP, Marian POP, Grigore Aloizu DOGARU, Vladimir C. BACAREA. A Web-based Nutritional Assessment Tool. Studies in Informatics and Control. 2013;22(3):307-314.
5. Ho M, Garnett SP, Baur LA, Burrows T, Stewart L, Neve M, Collins C. Impact of dietary and exercise interventions on weight change and metabolic outcomes in obese children and adolescents: a systematic review and meta-analysis of randomized trials. JAMA Pediatr. 2013;167(8):759-68.
6. Gibson LJ, Peto J, Warren JM, dos Santos Silva I. Lack of evidence on diets for obesity for children: a systematic review. Int J Epidemiol. 2006;35(6):1544-52.
7. U.S. Department of Agriculture and U.S. Department of Health and Human Services 7th Ed. Dietary Guidelines for Americans. Washington D.C: U.S. Government Printing Ofice; 2010. Available from: http://health.gov/dietaryguidelines/dga2010/DietaryGuidelines2010.pdf.
8. Lourenço BH, Arthur T, Rodrigues MD, Guazzelli I, Frazzatto E, Deram S, Nicolau CY, Halpern A, Villares SM. Binge eating symptoms, diet composition and metabolic characteristics of obese children and adolescents. Appetite. 2008;50(2-3):223-30.
9. Atkin LM, Davies PS. Diet composition and body composition in preschool children. Am J Clin Nutr. 2000;72(1):15-21.
10. Carmen Gabriela Barbu, Monica Delia Teleman, Alice Ioana Albu, Anca Elena Sirbu, Sorina Carmen Martin, Adrian Bancescu, Simona Vasilica Fica. Obesity and eating behaviors in school children and adolescents – data from a cross sectional study from Bucharest, Romania. BMC Public Health. 2015;15:206.
11. Elena Buhociu, Lygia Alexandrescu, Iuliana Paşol. Study on Eating and Life Habits to Romanian Students of 10-11 Years Old. Procedia - Social and Behavioral Sciences. 2014;117:690-4.
12. Clavien H, Theintz G, Rizzoli R, Bonjour JP. Does puberty alter dietary habits in adolescents living in a western society? J Adolesc Health. 1996;19(1):68-75.
13. Heli Griinberg, Kiilli Mitt, Maie Thetloff. Food habits and dietary intake of schoolchildren in Estonia. Scandinavian Journal of Nutrition. 1997;41:18-22.
14. Klesges RC, Stein RJ, Eck LH, Isbell TR, Klesges LM. Parental influence on food selection in young children and its relationships to childhood obesity. Am J Clin Nutr. 1991;53(4):859-64.
15. Frary CD, Johnson RK, Wang MQ. Children and adolescents' choices of foods and beverages high in added sugars are associated with intakes of key nutrients and food groups. J Adolesc Health. 2004;34(1):56-63.
16. Acharya K, Feese M, Franklin F, Kabagambe EK. Body mass index and dietary intake among Head Start children and caregivers. J Am Diet Assoc. 2011;111(9):1314-21.

Correspondence to:

Raluca-Monica Pop
Department of Endocrinology,
Emergency County Hospital, Tîrgu-Mureş,
Gheorghe Marinescu Street, 50,
Romania
E-mail: ralucapetri@yahoo.com

ADRENOLEUKODYSTROPHY – THE DIAGNOSTIC AND THERAPEUTIC CHALLENGES

Cristina Ghervan[1], Codruța Nemeș[2], Jacques Young[3], Ana Valea[1], Alina Silaghi[1], Liviu Ghervan[4]

Abstract

Adrenoleukodystrophy (ALD) is a genetically determined disorder, with recessively X-linked inheritance, manifested by: progressive cerebral demyelination, primary adrenocortical failure and testicular impairment. The affected gene is *ABCD1*, which codes for a peroxisomal membrane protein implicated in the beta-oxidation of very long-chain saturated fatty acids (VLCFA). In affected patients VLCFA are accumulating within the cells, primarily in the nervous system white matter, in the adrenal cortex and in testis. Three mean phenotypes of ALD are described: the childhood cerebral form (CCALD) the most severe, adrenomyeloneuropathy with adult onset (AMN) and isolated adrenal failure (Addison-only).

We present the case of a male patient diagnosed with: Addison's disease at age 7, hypergonadotropic hypogonadism and AMN at age 21, showing the diagnostic and therapeutic difficulties in the context of our country. The diagnosis of ALD is based on the determination of VLCFA in plasma and is confirmed by molecular genetic testing of the *ABCD1* gene locus, both not available in Romania. Concerning the treatment, besides hormonal replacement therapy, the options in order to prevent the occurrence and progression of neurological symptoms are limited: Lorenzo's oil is used therapeutically to normalize VLCFA but its impact upon neurological disorders is largely debated; hematopoietic stem cell transplantation is shown to be beneficial in mild CCALD, but this effect was not proved for AMN; gene therapy showed good results in experimental animal studies and seems to be a promising perspective for the future, but none are at that time available in Romania.

Key words: adrenoleucodystrophy, Addison's disease, hypergonadotropic hypogonadism

Introduction

Adrenoleukodystrophy (ALD) is a genetically determined disorder, with recessively inherited X-linked inheritance, manifested mainly in male subjects, associated with progressive cerebral demyelination, primary adrenocortical failure and testicular impairment. The affected gene is *ABCD1*, which codes for a peroxisomal membrane protein (adrenoleukodystrophy protein – ALDP) implicated in the beta-oxidation of very long-chain saturated fatty acids (VLCFA). If the enzyme is missing or not acting properly, the peroxisome dysfunction leads to the accumulation of VLCFA within the cells, primarily in the central nervous system (CNS) white matter and axons, in the adrenal cortex and in testis (1). The combined incidence of hemizygotes (all phenotypes) plus heterozygous female carriers is 1:16,800 newborns (2).

In 1923 Siemerling and Creutzfeldt reported a seven years old boy with adrenal failure due to the atrophy of the adrenal cortex and diffuse cerebral sclerosis. In 1963 an X - linked mode of inheritance was suggested, and in the mid-1970s this disease was named adrenoleukodystrophy. In 1976 the accumulation of VLCFA in the brain and adrenal cortex was reported, and in 1980, respectively in 1981 raised concentrations of VLCFA were shown in cultured skin fibroblasts and plasma. The defective peroxisomal enzyme and the responsible gene were identified in 1981 (1,3). The *ABCD1* gene is located on the long (q) arm of the X chromosome at position 28.

Three mean phenotypes of ALD have been described: the childhood cerebral form (cALD) (30-35% - the most severe), adrenomyeloneuropathy (AMN) (40-46% -) and isolated adrenal failure (´´Addison-only´´). Other rare forms are: the adolescent and adult cerebral form (a milder phenotype of the adult) and asymptomatic forms (1).

In cerebral forms, the accumulation of VLCFA in the brain leads to inflammatory demyelination, resulting in confluent and bilaterally symmetric loss of myelin, the parieto-occipital regions being usually affected first, with asymmetric progression of the lesions toward the frontal or temporal lobes. Children with the cerebral form of ALD experience learning and behavioral problems that usually begin between the ages of 4 and 10.

Over time the symptoms worsen, and these children may have difficulty reading, writing, understanding speech, and comprehending written material. Additional signs and symptoms of the cerebral form include aggressive behavior, vision problems, difficulty swallowing, poor coordination, and impaired adrenal gland function.

[1]Endocrinology Department, County Clinical Emergency Hospital Cluj-Napoca.
[2]Endocrinology Outpatient Facility, County Emergency Hospital Satu-Mare.
[3]Service d'Endocrinologie et Maladies de la Reproduction, Hôpital Bicêtre (Paris).
[4]Urology and Renal Transplantation Institute Cluj-Napoca.
E-mail: cghervan@yahoo.com, neagu_codruta@yahoo.com, jacques.young@wanadoo.fr, ana74us@yahoo.com, alinasilaghi@yahoo.com, liviughervan@yahoo.com

The rate at which this disorder progresses is variable but can be extremely rapid, often leading to total disability within a few years. The life expectancy of individuals with this type depends on the severity of the signs and symptoms and how quickly the disorder progresses, usually surviving only a few years after symptoms begin.

Adrenomyeloneuropathy (AMN) affects mainly the long tracts of the spinal cord; the affected individuals developing a degenerative axonopathy (4). Signs and symptoms appear between early adulthood and middle age. Affected individuals develop progressive stiffness and weakness in their legs (paraparesis), experience urinary and genital tract disorders, and often show changes in behavior and thinking ability. Most people with AMN also have adrenocortical insufficiency. In some severely affected individuals, damage to the brain and nervous system can lead to early death.

People with ALD whose only symptom is adrenocortical insufficiency are said to have the *Addison disease only form* (about 10% of cases). In these individuals, adrenocortical insufficiency can begin anytime between childhood and adulthood. However, most affected individuals develop the additional features of the AMN by the time they reach middle age. The life expectancy of individuals with this form depends on the severity of the signs and symptoms, but typically this is the mildest of the three types.

Adrenal insufficiency is also present in over 70% of cerebral or AMN forms. Although ALD is a rare cause of adrenal failure, *it is the most common cause of Addison's disease in young men* (5,6,7).

Rarely, individuals with X-linked ALD develop multiple features of the disorder in adolescence or early adulthood. In addition to adrenocortical insufficiency, these individuals usually have psychiatric disorders and a loss of intellectual function (dementia). It is unclear whether these individuals have a distinct form of the condition or a variation of one of the previously described types. For reasons that are unclear, different forms of X-linked ALD can be seen in affected individuals within the same family, harboring the same mutation.

Primary hypogonadism is also affecting the patients with ALD. The accumulation of VLCFA within the testis determine: hypocellularity and mild vacuolation of seminiferous tubules, and interstitial damage – i.e. focal fibrosis, near hyalinized tubules and reduction of the number of Leydig cell clusters per seminiferous tubule (8,9).

The diagnosis of ALD is based on the determination of VLCFA in plasma and is confirmed by molecular genetic testing of the *ABCD1* gene locus (6). Unfortunately there is still no effective treatment or strategy to predict the evolution of the disease (10).

We describe a case of adrenoleukodystrophy in a 21 years old young man, known with idiopathic Addison's disease by the age of 7, associated at the moment of diagnosis with hypogonadism, short stature, without neurological signs.

Case report

A 21 years old male patient was admitted in the emergency unit (ER) in August 2011 for asthenia, weakness, dizziness, nausea, vomiting, abdominal pain, salt craving, dyspnea, facial pallor and cold sensitivity; the symptoms occurring suddenly after sustained physical effort and sun exposure. The patient was diagnosed at the age of 7 with primary adrenal insufficiency and treated with glucocorticoid and mineralocorticoid substitution (prednisone and fludrocortisone) until 2007 when the treatment was discontinued by the pediatrician. In the presence of hyponatremia (124 mEq/l), hyperkalemia (6 mEq/l), metabolic acidosis (pH=7,3), leukocitosis (10800/mm³), uremia (blood urea nitrogen = 52 mg/dl) and rhabdomyolysis (TGO = 54U/L, CPK = 727U/L) adrenal crisis was diagnosed, subsequently confirmed by the low levels of cortisol: 8:00am = 20.9 nmol/l (n.r. 171-536) and 8:00pm = 12,4 nmol/l (n.r. 64-340), measured before ER admission. After the emergency treatment with hydrocortisone hemisuccinate i.v, rehydration and correction of electrolytes and acid-base imbalance, the patient was transferred in the Endocrinology department.

The clinical features at admission in our service are summarized in Table I and the laboratory and imaging tests in Table II.

Table I. Clinical examination performed at the admission in our unit.

Clinical examination
• Severe asthenia, • Hypothermia (<35ºC), cold skin. • Height = 153 cm (-3,5 DS below the mean) • Proportionate somatic development (arm span to height ratio = 0,98, the upper segment to lower segment ratio = 0,96) • Weight = 43 Kg, underweight (body mass index (BMI) of 18,36 kg/m^2), • Facial pallor • Generalized hyperpigmentation of the skin, increased in sun-exposed areas and over pressure areas (elbows and knees). • Supine blood pressure = 90/60 mmHg, orthostatic blood pressure = 80/60 mmHg, heart rate = 90 bpm; • Reduced facial hair growth, reduced axillar and pubic hair – stage Tanner III, right testicular volume = 12 ml, left testicular volume = 11 ml, penile length = 8 cm;

Table II. Laboratory tests and imaging.

Examination	Results	Observations/Interpretations
Laboratory tests	8 AM serum cortisol = 448,6 ng/dl (75-225)	Considering the ER **treatment** with hydrocortisone, the low values of cortisol measured before the ER admission and the pre-existing diagnosis of Addison's disease, we didn't complete the investigations with plasma ACTH level and the stimulation testing with 100µg Synacthen.
	Electrolytes: Na^+ = 138 mmol/l, K^+= 5.23 mmol/l	**Mineralocorticoid deficiency**
	DHEAS = 0,22 µg/ml (1-4,2)	**Adrenal androgen deficiency**
	FSH = 8,17 U/l (1-10,5), LH = 11,4 U/L (1-5,8), Testosterone = 2,06 ng/ml (2,5-10) (initial values) <u>Stimulation test with 100 µg Diphereline s.c:</u> Bazal 4 h 24 h FSH (U/l) 38,5 41,1 30,4 LH (U/l) 35,2 67,1 47,2 Testosterone 1,58 2,04 2,03 (ng/ml)	**Primary hypogonadism.**
	IGF1 = 88,6 ng/ml (116-368)	Previous normal values of IGF1 and basal and stimulated GH excluded GH deficiency. The punctual low level of IGF1 was interpreted as reaction to the distress of the adrenal crisis.
	PRL = 23,7 ng/ml (2-12)	The mild elevated PRL was interpreted as reaction to the distress of the adrenal crisis.
	TSH = 5,65 µU/ml (0,5-4) FT4 = 1,30 ng/dl (0,8-1,4) ATPO - negative	The slight elevation of TSH with normal FT4, negative ATPO and normal sonography was interpreted as reaction to the distress of the adrenal crisis "thyroid sick syndrome".
Thyroid sonography	Normal thyroid volume and structure	
Native adrenal CT-scan	*Very small adrenals*, difficult to individualize, measuring only 3-4 mm.	**Adrenal atrophy**
Immunology	Antiadrenal antibodies – negative	**Autoimmune etiology is excluded**
Pituitary MRI and FLAIR sections for brain	No pituitary injuries; **Multiple *demyelination areas*** in the subcortical white matter of frontal lobes, adjacent to the body of right lateral ventricle and genu of the corpus callosum	**Demyelinating disease**
Radiographs ies of the left hand and the knees.	The growth cartilages *are closed;* The bone age corresponds to the chronological age.	**Post-pubertal onset of hypogonadism.**

The association between adrenal failure, cerebral demyelination areas and hypogonadism raise suspicion of adrenoleukodystrophy, and the patient was transferred in the Neurology Department for etiologic and differential diagnosis of the demyelinating lesions: the tests performed are described in Table III.

Table III. Neurologic evaluation.

Examinations	Results
Neurological physical examination	Without neurological signs excepting a *slightly increased reflexes*.
Laboratory tests	
- **Immunology**	- IgA, IgG, IgM, CRP – normal values - ANA negative - CIC = 200 Ux10^{-3} (<150), - IgG Borellia - negative **- IgM Borellia - reactive**
- **Spinal fluid**	- total protein = **76mg/dl** (<50) - **positive** Pandy reaction - normal glucose and IgG - bacteriological and immunological examinations without abnormalities
Psychological examination	- normal intellect - MMSE: 30 points of 30 - personality examination revealed no psychopathological elements
Electro-neurography	- **motor axonal polyneuropathy**

Other causes for the demyelinating lesions being excluded, the probable diagnosis was ADL "Addison only form" but the confirmation needed the dosage of VLCFA, or the identification of the mutation of the *ABCD1* gene, both not available at the time in our country.

The patient was prescribed chronic replacement therapy: prednisone 7,5 mg/day, fludrocortisone 0,1 mg/day and testosterone undecanoate 40 mg/day (80 mg/day starting the second year). B-complex vitamins were prescribed in order to prevent further evolution of the demyelinating lesions and of axonal polyneuropathy. Lorenzo's oil, a specific treatment of ALD is not available in our country.

The clinical evolution with substitution therapy was very good, with weight gain, disappearance of fatigue, appetite normalization, normalization of testosterone level and progression of secondary sexual characteristics. The MRI evaluations in the next two years, showed a stationary size of the demyelinating lesions in the frontal lobes (Figure 1), but with intense gadolinium enhancement of the rim of the lesions from the rostrum and the genu of the corpus callosum, meaning active lesions (Figure 2). Despite this aspect, the patient is still neurologically asymptomatic.

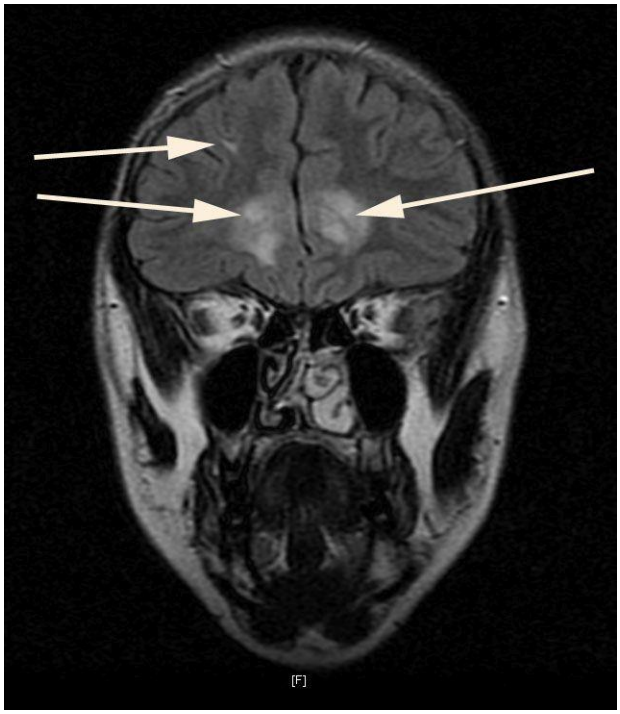

Fig. 1. MRI coronal section FLAIR showing demyelinating lesions (arrows).

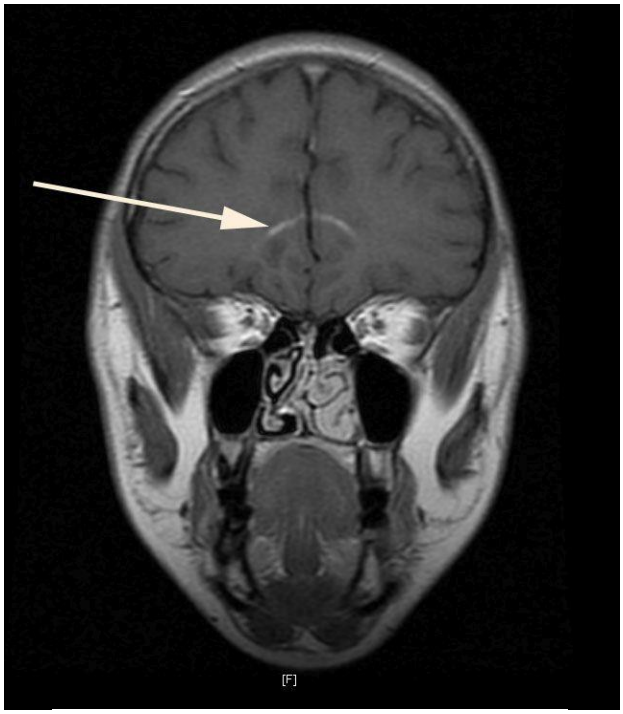

Fig. 2. MRI coronal section with gadolinium contrast showing marginal enhancement of the demyelinating lesions (arrow).

After two years, with the generous contribution of Prof. Jacques Young, Service d'Endocrinologie et Maladies de la Reproduction, Hopital Bicetre (Paris) and the contribution of the "Centre de Genetique Moleculaire et Chromosomique" Hopital Saint Vincent de Paul (Paris) the molecular genetic testing of the *ABCD1* gene locus showed that the patient is hemizygous for the mutation c.521A>G (p.Tyr174Cys), in exon 1, finally confirming the diagnosis of Adrenoleukodystrophy.

Discussions

Despite Addison's disease onset was at the age of 7, its etiology was never investigated. Moreover, at the age of 17 the substitution therapy was completely stopped by the pediatrician who said at that time that the illness was cured...

Adrenal failure is present in 90% of the boys and in 65% of the adults with ALD; it may precede, it can be concurrent or it can follow neurological signs. Desloques *el al.* reported a case of a young man diagnosed with cerebral ALD at the age of 29 who had been diagnosed with Addison's disease at the age of 8. The longest time reported between the diagnosis of Addison's disease and neurological manifestations in ALD is 32 years (11). Sydney *et al.* have published another case of idiopathic Addison's disease diagnosed at the age of 10 who eventually developed AMN at the age of 24 (12). Another study found that out of eight males with childhood-onset Addison's disease and no signs or symptoms of neurologic dysfunction; five had the biochemical defect of ALD and clear evidence by MRI examination of ALD involving the brain (13). These cases show that when Addison's disease is diagnosed in a young man, apparently without neurological signs, it still may be considered a manifestation of ALD.

In our case the patient had no neurological complaints at the time of presentation, the neurological examination revealed only slightly increased reflexes and the ENG examination noted motor axonal polyneuropathy. We interpreted the case as „Addison-only" that lately developed cerebral lesions. However, as shown, the risk of developing neurological manifestations in the ´´Addison-only´´ form is very high (3,6).

Long-term analysis of "Addison only" forms showed that all patients, who survive over adulthood will in the end develop AMN (1). The presence of motor axonal polyneuropathy may be the evidence of this evolution. If polyneuropathy is investigated, an axonopathy is found in the majority of the AMN patients, but this is rarely the initial symptomatology (14). The average age of developing neurological manifestations (spasticity and weakness of the legs, sphincter and sexual dysfunction) in AMN is 27,6 years. About 50% to 60% of AMN patients show subtle neuropsychological abnormalities, with the pattern of subcortical dementia (15).

In our patient, considering the presence of brain active demyelinating lesions on MRI, it may be an AMN with cerebral involvement. As shown, approximately 40%-45% of individuals with AMN show some degree of brain involvement on MRI or during clinical examination, but only in 10%-20% of them the brain involvement becomes severely progressive and leads to serious cognitive and behavioral disturbances that may progress to total disability and death (6). Although patients with AMN generally do not have clinical signs of brain involvement, up to 50% of them have MRI evidence of cerebral demyelination (16) and about one-third of them develop a rapid progressive cerebral form similar to that seen in CCALD form (17). When cerebral demyelination occurs in adolescence or adulthood, the initial progression of symptoms is usually slower. The rapid neurologic decline, seen in the cerebral forms, is caused by a severe inflammatory demyelination process. Though, 10% of males with cerebral ALD or AMN with cerebral involvement may not reach this stage. The cerebral demyelinating process arrests spontaneously and the patient can remain stable for a decade or even longer. But even after a 10 –15 years period of stability, sudden onset of rapid neurologic deterioration may occur. Once the cerebral demyelinating lesions have entered the active phase, with gadolinium enhancement, the prognosis is poor (14). In our patient, despite the "active phase aspect" of the lesions from the rostrum and the genu of the corpus callosum in MRI, the neurologic signs are still lacking.

In 85% of the cerebral ALD cases the demyelinating lesions occur in the bilateral occipito-parietal regions. In this case the demyelinating lesions are located in the frontal lobes, adjacent to the body of the right lateral ventricule and the genu of the corpus callosum. This version is seen in about 15% of the cases (1,15,18). Because of this particular location, the differential diagnosis with other demyelinating diseases was needed and it was predominantly based on neurological and cerebrospinal fluid examination. The suggestive changes of multiple sclerosis (moderate pleocytosis, discrete increase of protein level, increased amount of IgG) and of Lyme disease (moderate lymphocytic pleocytosis, increased protein level (1-3 g/l), normal or low glucose) weren't observed in our patient. Despite the reactive IgM for Borellia at ELISA testing, due to the absence of the symptoms and of the specific cerebrospinal fluid changes, the neuroboreliosis was excluded. The result was interpreted as being false positive considering that ELISA IgM anti Borellia can be positive in a variety of other diseases, including neurological ones (19,20,21,22).

Although the determination of VLCFA wasn't possible, the genetic testing confirmed the diagnosis of andrenoleukodystrophy. It is well known that there is no genotype-phenotype correlation and also that all clinical phenotypes arise from identical mutations [23]. The mutation found in our patient, c521A>G (pTyr174Cys), was described many times before, including one case of "Addison-only" (24), one Chinese (25) and one Japanese (26) patient with childhood cerebral ALD and in a large Arab family with ALD (27). This mutation, located in the exon 1 of the *ABCD1* gene leads to the absence of ALDP in fibroblasts as indicated by immunofluorescence and /or immunoblotting.

The association of primary adrenal failure with hypogonadism raised also the suspicion of DAX1 mutation, even more with the initial normal value of FSH and only slightly increases of LH. Another hypothesis was adrenal

enzyme deficiency - partial StAR protein deficiency, which affects steroid hormone producing cells and is manifested by lipoid adrenal hyperplasia, and adrenal and gonadal failure. Therefore, we decided to complete the investigations with adrenal CT scan and brain/pituitary MRI and the hormonal profile with the stimulation test with 100 µg Diphereline. Abdominal CT showed adrenal atrophy, the Diphereline test showed hypergodotropic hypogonadism and the MRI showed demyelinating lesions of the brain, excluding these etiologies. The initial normal values of gonadotropins were subsequently interpreted as being due to the administration of hydrocortisone succinate for the treatment of Addison crisis (the excess of glucocorticoids inhibits the release of gonadotropins) (29). We also excluded hemochromatosis and the most common etiology of Addison's disease – the autoimmune disease.

The scarce secondary sexual characteristics, with testicular development and closure of growth cartilages, without bone age retardation, lead to the idea that hypogonadism occurred after a partial puberty.

The testicular impairment is present in 77-80% of ALD patients (8,9). The accumulation of striated material (lipid accumulation), that leads to atrophy and death of the cells is seen in: adrenal cells, Schwann cells, brain macrophages and testicular interstitial cells (30). The testicular histological changes, described by Powers and Schaumburg since 1981, consist in hypo cellularity, vacuolization of seminiferous tubules, hyalinization of tubules and reduced number of Leydig cells (31).

We also revealed a slightly increased TSH, with normal free T4 and a normal thyroid gland in ultrasound examination. These elements were also mentioned to by Aversa *el al.* and interpreted like ''euthyroid sick syndrome'' (32). The short stature is another simultaneous element. The low value of IGF1 corresponding to sex and age, in the presence of normal basal and after stimulation GH levels, was interpreted as being appropriate to pubertal stage.

Concerning the treatment, besides glucocorticoid, mineralocorticoid and androgen replacement therapy, the options in order to prevent the occurrence and progression of neurological symptoms are limited.

Lorenzo's oil, a combination of 4/1 mix of erucic acid and oleic acid, is used therapeutically to normalize VLCFA levels. The daily doses are 20% of the caloric needs. Several studies have shown that, despite Lorenzo's Oil reduces and even normalizes plasma levels of VLCFA, it doesn't prevent progression of brain demyelinating lesions in cerebral forms (33,34,35,36). Regarding the patients with AMN, there is some evidence that this therapy stabilizes or even improves neurological disorders (35), but other studies have shown the inefficiency of the treatment, with clinical deterioration and progression (36,37,38). Lorenzo's Oil isn't available in Romania, but certain oils used in cooking, such as *mustard seed oil*, have naturally high levels of erucic acid and thus can lead to a decrease in VLCFA similar to that observed with Lorenzo's oil therapy.

Hematopoietic stem cell transplantation is shown to be beneficial in CCALD, for asymptomatic or mild symptomatic patients, but this effect was not proved for AMN or adult cerebral ALD patients. The data showed that hematopoietic stem cell transplantation performed at an advanced stage of the cerebral ALD would accelerate the progression of the disease; good clinical outcome is achieved only when hematopoietic stem cell transplantation is performed at the very early stage of the disease. Immunomodulatory and immunosuppressive therapies were proved ineffective. Valproic acid may be beneficial in patients with AMN; other therapies under trial are: 4 phenylbutyrate and antioxidants (14,39).

Gene therapy showed experimental promising results in animal studies. Gong group used recombinant adeno-associated virus serotype 9 (rAAV9) vector for delivery of the human *ABCD1* gene to mouse central nervous system (CNS). In vitro, efficient delivery of *ABCD1* gene was achieved in primary mixed brain glial cells from Abcd1-/- mice as well as X-ALD patient fibroblasts. Importantly, human ABCD1 localized to the peroxisome, and AAV-ABCD1 transduction showed a dose-dependent effect in reducing VLCFA. In vivo, AAV9-ABCD1 was delivered to Abcd1-/- mouse CNS by either stereotactic intracerebroventricular (ICV) or intravenous (IV) injections. Astrocytes, microglia and neurons were the major target cell types following ICV injection, while IV injection also delivered to microvascular endothelial cells and oligodendrocytes. IV injection also yielded high transduction of the adrenal gland. Importantly, IV injection of AAV9-ABCD1 reduced VLCFA in mouse brain and spinal cord. They conclude that AAV9-mediated *ABCD1* gene transfer is able to reach target cells in the nervous system and adrenal gland as well as reduce VLCFA in culture and a mouse model of X-ALD (40).

Conclusions

Adrenoleukodystrophy is a rare disease and is certainly underdiagnosed due to multiple phenotypes, in which the diagnosis is often delayed, especially if the adrenal failure precedes the neurological symptoms. Thus, we support the importance of ALD testing, especially for the male patients diagnosed with idiopathic Addison's disease in childhood. At least the dosage of VLCFA must be available and reimbursed by the medical insurance system.

Particular aspects of the case are:

- The association of primary adrenal insufficiency with hypogonadism and short stature that made necessary the differential diagnosis with other etiologies such as: DAX1 mutation, adrenal enzyme deficiency (partial deficiency of STaR protein) and pituitary failure;
- The atypical localization of the demyelinating lesions that required differential diagnosis with other causes of CNS demyelinating diseases, like multiple sclerosis and Lyme disease;
- The lack of neurological symptoms, despite the presence of the active demyelinating lesions of the cerebral white matter.

The major concern for the future is the evolution of the neurological lesions, even more since the therapeutic possibilities in our country are so limited.

References

1. Hugo WM. Adrenoleukodystrophy: phenotype, genetics, pathogenesis and therapy. Brain, 1997 Aug;120 (Pt 8):1485-1508.
2. Bezman L., Moser H.W. Incidence of X-linked adrenoleukodystrophy and the relative frequency of its phenotypes. Am. J. Med. Genet. 1998;76:415–419.
3. van Geel BM, Assies J, Wanders RJ, Barth PG. X linked adrenoleukodystrophy: clinical presentation, diagnosis, and therapy. J Neurol Neurosurg Psychiatry, 1997 Jul;63(1):4-14.
4. Powers JM, DeCiero DP, Ito M, Moser AB, Moser HW. Adrenomyeloneuropathy: a neuropathologic review featuring its noninflammatory myelopathy. J Neuropathol Exp Neurol 2000; 59(2):89-102.
5. Laureti S, Casucci G, Santeusanio F, Angeletti G, Aubourg P, Brunetti P. X-linked adrenoleukodystrophy is a frequent cause of idiopathic Addison's disease in young adult male patients. J Clin Endocrinol Metab, 1996 Feb;81(2):470-474.
6. Moser AB, Steinberg SJ, Raymond GV. X-Linked Adrenoleukodystrophy. In: Pagon RA, Bird TD, Dolan CR, Stephens K, editors. GeneReviews [Internet]. Seattle (WA): University of Washington, Seattle; 1993-1999 Mar 26 [updated 2009 Jun 02].
7. Ronghe MD, Barton J, Jardine PE, Crowne EC, Webster MH, Armitage M, Allen JT, Steward CG. The importance of testing for adrenoleucodystrophy in males with idiopathic Addison's disease. Arch Dis Child, 2002 Mar;86(3):185-189.
8. Brennemann W, Köhler W, Zierz S, Klingmüller D. Testicular dysfunction in adrenomyeloneuropathy. Eur J Endocrinol, 1997 Jul;137(1):34-39.
9. Assies J, Gooren LJ, Van Geel B, Barth PG. Signs of testicular insufficiency in adrenomyeloneuropathy and neurologically asymptomatic X-linked adrenoleukodystrophy: a retrospective study. Int J Androl, 1997 Oct;20(5):315-321.
10. Terre'Blanche G, van der Walt MM, Bergh JJ, Mienie LJ. Treatment of an adrenomyeloneuropathy patient with Lorenzo's oil and supplementation with docosahexaenoic acid-A case report. Lipids Health Dis, 2011 Aug 26;10:152.
11. Desloques L, Januel AC, Mejdoubi M, Catalaa I, Pariente J, Cognard C. [X-linked adult onset adrenoleukodystrophy. A case report]. J Neuroradiol, 2006 Jun;33(3):201-215.
12. Westphal SA. Adrenomyeloneuropathy presenting in adulthood. West J Med, 1998 Jan;168(1):45-47.
13. Sadeghi-Nejad A, Senior B. Adrenomyeloneuropathy presenting as Addison's disease in childhood. N Engl J Med, 1990; 322:13-16.
14. Engelen M, Kemp S, de Visser M, van Geel BM, Wanders RJ, Aubourg P, Poll-The BT. X-linked adrenoleukodystrophy (X-ALD): clinical presentation and guidelines for diagnosis, follow-up and management. Orphanet J Rare Dis. 2012 Aug 13;7:51
15. Kumar AJ, Köhler W, Kruse B, Naidu S, Bergin A, Edwin D, Moser HW. MR findings in adult-onset adrenoleukodystrophy. AJNR Am J Neuroradiol. 1995 Jun-Jul;16(6):1227-1237.
16. Spurek M, Taylor-Gjevre R, Van Uum S, Khandwala HM. Adrenomyeloneuropathy as a cause of primary adrenal insufficiency and spastic paraparesis. CMAJ, 2004 Oct 26;171(9):1073-1077.
17. Ferrer I, Aubourg P, Pujol A. General aspects and neuropathology of X-linked adrenoleukodystrophy. Brain Pathol. 2010 Jul;20(4):817-830
18. Castellote A, Vera J, Vazquez E, Roig M, Belmonte JA, Rovira A. MR in adrenoleukodystrophy: atypical presentation as bilateral frontal demyelination. AJNR Am J Neuroradiol, 1995 Apr;16(4 Suppl):814-815.
19. Bratton RL, Whiteside JW, Hovan MJ, Engle RL, Edwards FD. Diagnosis and treatment of Lyme disease. Mayo Clin Proc, 2008;83:566–571.
20. Hildenbranda P, Cravenb DE, Jonesc R, Nemeskald P. Lyme Neuroborreliosis: Manifestations of a Rapidly Emerging Zoonosis. AJNR, June 2009; 30:1079-1087.
21. Lana-Peixoto MA. Multiple sclerosis and positive Lyme serology. Arq Neuropsiquiatr 1994,52(4):566-571
22. Luque FA, Jaffe SL. Cerebrospinal fluid analysis in multiple sclerosis. Int Rev Neurobiol. 2007;79:341-356
23. Smith KD, Kemp S, Braiterman LT, Lu J-F, Wei H-M, Geraghty M, Stetten G, Bergin JS, Pevsner J, Watkins PA. X-linked adrenoleukodystrophy: genes, mutations, and phenotypes. Neurochem Res.1999;24:511–525.
24. Lachtermacher MB, Seuánez HN, Moser AB, Moser HW, Smith KD. Determination of 30 X-linked adrenoleukodystrophy mutations, including 15 not previously described. Hum Mutat. 2000;15(4):348-353
25. Lan F, Wang Z, Xie H, Huang L, Ke L, Yang B, Zhu Z. Molecular diagnosis of X-linked adrenoleukodystrophy: experience from a clinical genetic laboratory in mainland China with report of 13 novel mutations. Clin Chim Acta. 2011 May 12;412(11-12):970-974
26. Shimozawa N, Honda A, Kajiwara N, Kozawa S, Nagase T, Takemoto Y, Suzuki Y. X-linked adrenoleukodystrophy: diagnostic and follow-up system in Japan. J Hum Genet. 2011 Feb;56(2):106-109.
27. Neumann S, Topper A, Mandel H, Shapira I, Golan O, Gazit E, Loewenthal R. Identification of new mutations in Israeli patients with X-linked adrenoleukodystrophy. Genet Test. 2001 Spring;5(1):65-68.
28. Korenke GC, Roth C, Krasemann E, Hüfner M, Hunneman DH, Hanefeld F. Variability of endocrinological dysfunction in 55 patients with X-linked adrenoleucodystrophy: clinical, laboratory and genetic findings. Eur J Endocrinol,1997 Jul;137(1):40-47.
29. Aron DC, Findling JW, Tyrrell JB. Glucocorticoids & Adrenal Androgens. In: Gardner DG, Shoback D, eds. Greenspan's Basic & Clinical Endocrinology 8th edition. US: The McGraw-Hill Companies, 2007:346-395.

30. Powers JM, Schaumburg HH. Adreno-leukodystrophy (sex-linked Schilder's disease). A pathogenetic hypothesis based on ultrastructural lesions in adrenal cortex, peripheral nerve and testis. Am J Pathol,1974 Sep;76(3):481-491.
31. Powers JM, Schaumburg HH. The testis in adreno-leukodystrophy. Am J Pathol, 1981 Jan;102(1):90-98.
32. Aversa A, Palleschi S, Cruccu G, Silvestroni L, Isidori A, Fabbri A. Rapid decline of fertility in a case of adrenoleukodystrophy. Hum Reprod, 1998 Sep;13(9):2474-2479.
33. Rizzo WB, Leshner RT, Odone A, Dammann AL, Craft DA, Jensen ME, Jennings SS, Davis S, Jaitly R, Sgro JA. Dietary erucic acid therapy for X-linked adrenoleukodystrophy. Neurology, 1989 Nov;39(11):1415-1422.
34. Uziel G, Bertini E, Bardelli P, Rimoldi M, Gambetti M. Experience on therapy of adrenoleukodystrophy and adrenomyeloneuropathy. DevNeurosci, 1991;13 (4-5):274-279.
35. Asano J, Suzuki Y, Yajima S, Inoue K, Shimozawa N, Kondo N, Murase M, Orii T. Effects of erucic acid therapy on Japanese patients with X-linked adrenoleukodystrophy. Brain Dev, 1994 Nov-Dec;16(6):454-458.
36. Korenke GC, Hunneman DH, Kohler J, Stöckler S, Landmark K, Hanefeld F. Glyceroltrioleate /glyceroltrierucate therapy in 16 patients with X chromosomal adrenoleukodystrophy /adrenomyeloneuropathy: effect on clinical, biochemical and neurophysiological parameters. Eur J Pediatr, 1995;154:64–70.
37. Aubourg P, Adamsbaum C, Lavallard-Rousseau MC, Rocchiccioli F, Cartier N, Jambaque I, Jakobezak C, Lemaitre A, Boureau F, Wolf C, Bougneres PF. A 2 year trial of oleic and erucic acids (Lorenzo's oil) as treatment for adrenomyeloneuropathy. N Engl J Med, 1993; 329:745–752.
38. van Geel BM, Assies J, Haverkort EB, Koelman JH, Verbeeten B Jr, Wanders RJ, Barth PG. Progression of abnormalities in adrenomyeloneuropathy and neurologically asymptomatic X-linked adrenoleukodystrophy despite treatment with "Lorenzo's oil". J Neurol Neurosurg Psychiatry, 1999 Sep;67(3):290-299.
39. Berger J, Pujol A, Aubourg P, Forss-Petter S. Current and future pharmacological treatment strategies in X-linked adrenoleukodystrophy. Brain Pathol, 2010 Jul;20(4):845-856.
40. Gong Y, Mu D, Prabhakar S, Moser A, Musolino P, Ren J, Breakefield XO, Maguire CA, Eichler FS. Adeno-associated virus serotype 9-mediated gene therapy for X-linked Adrenoleukodystrophy (X-ALD). Mol Ther. 2015, 23(5):824-834.
41. Jiang MY1, Cai YN, Liang CL, Peng MZ, Sheng HY, Fan LP, Lin RZ, Jiang H, Huang Y, Liu L. Clinical, biochemical, neuroimaging and molecular findings of X-linked Adrenoleukodystrophy patients in South China. Metab Brain Dis. 2015 Aug 12. [Epub ahead of print]

Correspondence to:

Associate Professor Cristina Ghervan, MD, PhD.
Department of Endocrinology,
University of Medicine and Pharmacy "Iuliu Hatieganu"
3-5 Pasteur street, Cluj-Napoca, Romania
Tel: 0744398417
E-mail: cghervan@yahoo.com

ENDOCRINE ABNORMALITIES IN CHILDREN WITH OBSTRUCTIVE SLEEP APNEA

Marcovici Tamara[1,2], Giorgiana Brad[1,2], Delia Nicoara[1,2], Maria Puiu[1,2], Maria Papa[1,2], Alina Grecu[2]

Abstract

Introduction. Obstructive sleep apnea (OSA) is more common in children with obesity. Episodic nocturnal hypoxemia, hypercapnia and sleep fragmentation result in reduced release of GH (growth hormone) during sleep and onset of the short stature. In children with Down syndrome predisposition to SAO is dependent on oropharyngeal anatomical peculiarities and obesity is an aggravating factor. The association of hypothyroidism emphasizes the cognitive deficit due to trisomy 21 and obstructive sleep apnea. Compromising somatic growth is a powerful long-term consequence in children with OSA.

Material and method. We present the case of a 9 year and 11 months old boy with Down syndrome known with sleep apnea in which the periodic clinical and laboratory assessment identified the presence of thyroid hypofunction.

Results. The patient is obese (BMI = 22. 5 kg / m2 at the 95th percentile for gender and age), with mild subclinical hypothyroidism (TSH = 5.71 uIU/mL, FT3 = 6.82 pmol/L, FT4 = 14. 27 pmol/L) and residual SAO after tonsils and adenoids ablation. Sleep polygraphy revealed mixed apnea, predominantly obstructive, with apnea-hypopnea index = 18. 3/hour, average SaO2 = 95%, desaturation index = 20.5/hour. Substitution with potassium iodide was initiated. It was recommended hypocaloric diet, lateral decubitus posture during sleep and reevaluation in order to initiate CPAP.

Conclusions. Annual assessment of thyroid function in patients with Down's disease is mandatory. Hypothyroidism, obesity and obstructive sleep apnea require interdisciplinary and individualized management in these patients.

Key words: obstructive sleep apnea, children, endocrine abnormalities

Introduction

Obstructive sleep apnea (OSA) is the most common type of apnea and it is due to structural abnormalities (changes in facial bones, jaw and tongue); enlarged tonsils and adenoids; decreased pharynx muscle tone; obesity, genetic syndromes, etc.[1,2,3,4,5] OSA consists of repeated interruptions of breathing during sleep lasting more than 10 seconds and hypopnea episodes.[4,6] Air circulation in the upper airways is disrupted, affecting the body's oxygenation.[1] Transient changes in blood gases (hypoxia, hypercarbia) and sleep fragmentation occur.[1] These events lead to cardiovascular abnormalities (tachycardia, hypertension), digestive problems (regarding gastro-oesophageal reflux), endocrine issues (reduced secretion of growth hormone, etc.), restless sleep and frequent awakenings, etc.[1,4,7,8,9] With time, complications occur: neuropsychiatric disorders (attention deficit, hyperactivity, irritability, aggression, memory disorders, school failure); growth deficiency; metabolic (increased insulin resistance); abnormal bone (infundibular sternum); cardio-pulmonary (pulmonary hypertension, cor pulmonale); frequent respiratory infections (recurrent otitis media).[1,2,10] They alter the quality of life leading to debilitating diseases (arrhythmias, congestive heart and respiratory failure) and even premature death.

The diagnosis of sleep apnea is achieved by night poligraphy. [2,5,6,9] This easy investigation which can be used in patients of any age is the gold standard in the management of sleep apnea. Early diagnosis and proper treatment of OSA prevent severe complications.[1]

Some endocrine and metabolic conditions can be associated with OSA.[1,3,4,5,11] There are more common in children with obesity. Episodic nocturnal hypoxemia, hypercapnia and sleep fragmentation result in reduced release of GH (growth hormone) during sleep and onset of the short stature.[2] Compromising somatic growth is a powerful long-term consequence in children with OSA. In children with Down syndrome predisposition to OSA is dependent of oropharyngeal anatomical characteristics and obesity is an aggravating factor. The association of hypothyroidism emphasizes the cognitive deficit due to trisomy 21 and obstructive sleep apnea.[6,11] Increasing severity of OSA is associated with greater insulin resistance (IR) and suggests that OSA is independently associated with glucose intolerance and worsened glycemic control.[1,4]

Purpose

To assess endocrine abnormalities in obstructive sleep apnea in children.

[1]„Victor Babes" University of Medicine and Pharmacy, Timisoara, Romania
[2]„Louis Turcanu" Emergency Children Hospital Timisoara, Romania
E-mail: t_marcovici@yahoo.com, giorgiana.brad@gmail.com, nicoara.delia@yahoo.com, maria.puiu@gmail.com, mariapapa@yahoo.com, agrecu@gmail.com

Materials and Methods

We present the case of a 9 year and 11 months old boy with Down syndrome known with sleep apnea in which the periodic clinical and laboratory assessment identified the presence of thyroid hypofunction.He was evaluated by: anamnesis (history of snoring, witnessed apneas), clinical exam, laboratory assessment (haemathology, biochemistry, hormonal, etc.); thyroid ultrasounds, sleep polygraphy; consults (ENT, neurology, cardiology, endocrinology).

Results

Anamnesis revealed intense night snoring during early childhood; mouth breathing, macroglossia and tonsillar hypertrophy grade III. At age 6 adeno-tonsillectomy was performed. Sleep polygraphy made in 2012 after surgery releaved mild sleep apnea with apnea hypopnea index (AHI)=3/hour, mean SaO2= 94% and desaturation index =18/hour (Figure 1). The patient was overweight (BMI=17.9 kg/m^2, at the 89th percentile for sex and age). In 2015 he was twice evaluated, in May, respectively in August. Actually, the patient is obese (in May: BMI = 20.8 kg/m^2, at 91th percentile for age and sex; in August: BMI = 22. 5 kg/m^2 at the 95th percentile for gender and age) (Figure 2). Intermittent snoring, vitamin D deficiency and hypocalcemia (Table 1), mild subclinical hypothyroidism (Table 2) and residual OSA after tonsils and adenoids ablation are present. Sleep polygraphy revealed mixed apnea, predominantly obstructive, with apnea-hypopnea index=18.3/hour, average SaO2 = 95%, desaturation index=20.5/hour. Cardiological evaluation (physical exam, cardiac ultrasonography, electrocardiogram) revealed normal relations. Substitution with potassium iodide was initiated. It was recommended treatment with oral calcium and vitamin D, hypocaloric diet, lateral decubitus posture during sleep and reevaluation in order to initiate CPAP.



Figure 1. Sleep study (2012).

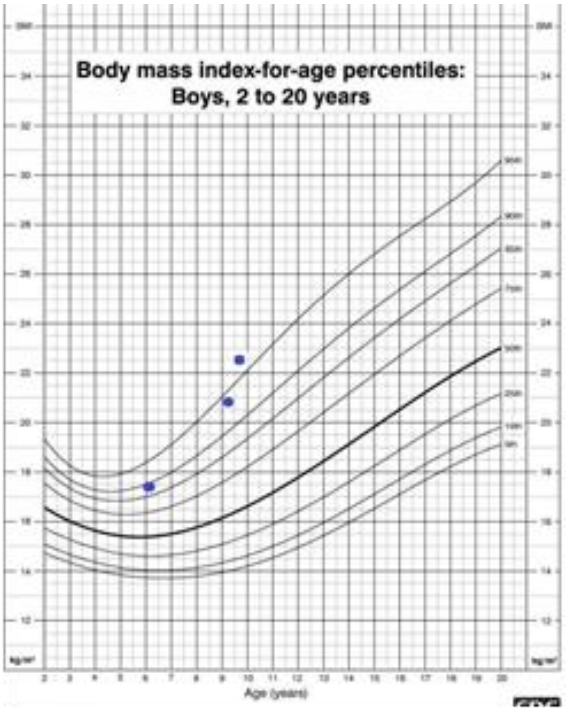

Figure 2. BMI evolution of the case presented.

Table 1. Biochemical evaluation.

Parameter	Result		Normal range
	May 2015	*August 2015*	
Total calcium (mmol/L)	2.24	2.28	2.3-2.75
Free calcium (mmol/L)	1.02	1.04	1.05-1.3
Magnesium (mmol/L)	0.99	-	0.7-1.05
Serum phosphate (mmol/L)	1.66	1.64	1.1-2
Alkaline phosphatase (U/L)	179	192	< 300
Total fat (g/L)	6.21	6.85	5-8
Glycemia (mg/dL)	87	90	60-99

Tabel 2. Hormone evaluation.

Parameter	Result		Normal range
	May 2015	*August 2015*	
FT3 (pmol/L)	6.82	6.24	4.1-7.9
FT4 (pmol/L)	14.27	16.66	11.6-21.5
TSH (uiU/mL)	5.71	4.37	0.66-4.14
25- hydroxy vitamin D (μg/L)	12.81	31.82	20-70
Parathormon	40.2	-	15-65

Predominance of male gender is one of the main risk factors for OSA.[1,3] The etiology of OSA is multifactorial.[3] It is associated with hypertrophic adenoids, hypertrophic rhinitis, low soft palate, deviations of oral structures, obesity and even hypothyroidism.[1,4] Comorbidities of OSA could be hypertension, insulin resistance, etc. Obesity is an important determinant of sleep apnea (SA) even in children.[1] 1-3% of non obese children aged less than 8 years present OSA, while obese children show OSA 4-5 times more frequently. The association of obesity with adenotonsillar hypertrophy worsens the obstructive sleep apnea. In these patients, the first-line therapy is adenotonsillectomy.[2] The OSA complications are more common in the obese. Hygienic-dietary regime is addressed to weight reduction. Down syndrome is often associated with obesity and obstructive sleep apnea (OSA).[7,8,12] In these children, obesity is an aggravating factor of OSA and BMI (Body Mass Index) and AHI (Apnea Hypopnea Index) correlates. In children with trisomy 21 obstructive sleep apnea (OSA) is frequent because of anatomical features. 60% of preschoolers with Down syndrome have sleep apnea, its incidence increasing with age.[2] Adenotonsillar hypertrophy contributes to worsening airway obstruction in these patients.[2] Neurocognitive impairment and OSA emphasizes nutritional status dependent pre-existing pathology. Identifying obstructive sleep apnea in children with trisomy 21 enables accurate and personalized interdisciplinary management of these cases.[2,10]

Hypothyroidism is characterized by a low level of thyroid hormones which may cause abnormal soft tissue thickening (myxedema) in the upper airway, a reduction in breathing control and weakness of the muscles that determine upper airway patency.[1,3,4,5,6] Hypothyroidism might cause OSA due mucoprotein deposition in the upper airway, decreased neural output to the upper airway musculature, obesity, and abnormalities in ventilator control. In patients with OSA, hypothyroidism is very uncommon.[5] Hypothyroidism can be associated with severe cases of OSA.[1,4] For OSA patients, the prevalence of clinical hypothyroidism is not higher than the in general population. It is essential to consider the risk factors for hypothyroidism when evaluating patients for sleep apnea as well as considering OSA risk factors when evaluating hypothyroid cases.[4] Routine blood testing for TSH and FT4 should be recommended for OSA patients with severe obesity, persistent sleepiness despite adequate CPAP therapy and with overt hypothyroid symptoms and signs. Conservative management of OSA contains weight reduction, sleeping positions adjustment, etc.[1,2,4]

However, when irreversible skeletal defects and/or obesity are present, OSA may persist despite treatment of endocrine disorders and may thus require complementary therapy. This is also frequently the case in patients with obesity, even after substantial weight reduction. Given the potential neurocognitive consequences and increased cardiovascular risk associated with OSA, CPAP therapy is recommended if OSA persists despite effective treatment of its potential causes.[1,2,4]

Because some features of hypothyroidism are similar to symptoms of OSA, it is mandatory to consider the possible coexistence of the two conditions. Decreased cognitive function and obesity are common findings in both disorders.[1]

Hypothyroidism is a well-known disorder in which OSA is relatively common. Hypothyroidism may contribute to sleep apnea through macroglossia or disruption of the muscles that control the upper airway.[3] If hypothyroidism is causing sleep apnea, it is improved with thyroid hormone substitution. Although treatment with thyroid replacement therapy will normalize hormones levels and reduce symptoms, OSA often persists and requires continued therapy.[1]

Undiagnosed or improperly treated OSA leads to significant morbidity, sometimes with irreversible consequences despite appropriate but late treatment. The consequences of OSA are correlated with episodic nocturnal hypoxemia, hypercapnia and sleep fragmentation.[2,4] Snoring in OSA changes the sleep architecture, reducing the release of GH during sleep.[2]

Hypothyroidism is particularly common in children with Down syndrome.[11] Although the association between Down's syndrome (DS) and thyroid dysfunction is well recognized, the cause of this condition is not known. Patients with trisomy 21 have an increased prevalence of both congenital hypothyroidism (28 times higher than in the general population) and acquired thyroid dysfunction.[11]

Beyond the newborn period, the incidence of elevated TSH values in Down syndrome increases. Mild plasma thyrotropin (TSH) elevation with normal thyroxine (T4) levels is the most commonly seen pattern of thyroid dysfunction in DS.[11] These biochemical deviations decreased with age – 70% of individuals with subclinical hypothyroidism in the first test had become normal in the second one, like in the case presented.

This is a treatable cause of mental retardation, thus early detection and treatment are essential in order to maximize cognitive abilities in this already impaired population. Current health supervision guidelines for

children with DS suggest reviewing results of the newborn thyroid function screen, then repeating thyroid function tests at the age of 6 months and 12 months, and then annually.[11] Because of the high prevalence of thyroid dysgenesis in Down syndrome, patients with thyroid dysfunction, lifelong treatment with L-thyroxine should be started without delay.[11]

OSA may have consequences on hormonal axes.[1] Variable degrees of hypogonadism are associated with OSA.[1] This impairment of pituitary-gonadal axis is linked to the degree of hypoxia and disordered breathing, independently of increasing age or obesity. In male patients, hypogonadism improves with CPAP. In females higher AHI (apnea-hypopnea index) is associated with lower serum estradiol and progesterone, suggesting that OSA may be associated with impaired ovarian function. OSA is also associated with hypoxia-induced sympathetic activation, which may contribute to hypertension via the stimulation of renin-angiotensin-aldosterone system.[1]

OSA is associated with a reduction in total sleep time and with sleep fragmentation, which can affect glucose tolerance as shown by several epidemiological studies.[1,2] Hypothyroidism and OSA show some clinical overlap.[1] An increased prevalence of OSA (between 25 and 35%) has been reported in patients with hypothyroidism. Central apnea may also be encountered in this setting. The main pathophysiological determinant of OSA in hypothyroidism seems to be pharynx narrowing due to soft tissue infiltration by mucopolysaccharides and protein.[6] These findings support the recommendation that thyroid hormones and TSH be measured in all patients with suspected or confirmed OSA, even if the prevalence of hypothyroidism is low. [4, 3,11]

Conclusions

The positive correlation between AHI and TSH supports the fact that thyroid function test screening is necessary in children with OSA. The measurement of TSH levels in suspected OSA cases may help both differential diagnosis between OSA and hypothyroidism, as well as diagnosis of subclinical hypothyroidism. Upper airway obstruction is related to obesity and male gender and not to hypothyroidism per se. Although testing of thyroid function is not recommended as part of the routine workup of patients with OSA, in Down syndrome is important to establish whether hypothyroidism is present. Annual assessment of thyroid function in patients with Down's disease is mandatory. Hypothyroidism, obesity and obstructive sleep apnea require interdisciplinary and individualized management in these patients.

References

1. Attal P, Chanson P. Endocrine Aspects of Obstructive Sleep Apnea. The Journal of Clinical Endocrinology &Metabolism; July 2, 2013; 95(2), pp. 483–95.
2. Marcovici T, Marginean O, Mihaicuta S, Zabos D. Managementul apneei in somn la copiii cu sindrom Down. Somnologie pediatrica, 2015, 1(2):34-7.
3. Krishnan PV, Vadivu AS, Alappatt A, Kameswaran M. Prevalence of sleep abnormalities and their association among hypothyroid patients in an Indian population. Sleep Medicine, December 2012Volume 13, Issue 10, Pages 1232–7.
4. Parmaksız ET, Salepçi B, Saraç G, Kıral N, Fidan A, Cömert S, Çağlayan B. Undiagnosed Hypothyroidism in Obstructive Sleep Apnea Syndrome. Journal of Turkish Sleep Medicine 2015; 2: 11-14.
5. Kapur VK, Koepsell TD, Demaine J, Hert R, Sandblom RE, Psaty BM. Association of Hypothyroidism and Obstructive Sleep Apnea. American Journal of Respiratory and Critical Care Medicine, 1998; 158(5):1379-83.
6. Mete T, Yalcin Y, Berker D, Ciftci B, Firat SG, Topaloglu O, Yavuz H C, Guler S. Relationship between obstructive sleep apnea syndrome and thyroid diseases. Endocrine, December 2013, 44 (3):723-8.
7. Lin SC, Davey MJ et al. Screening for obstructive sleep apnea in children with Down syndrome. The Journal of Pediatrics, online, 27 March 2014.
8. Tauman R, Gozal D. Obstructive sleep apnea in children. Expert Rev Resp Med 2011; 5(3):425-40.
9. Marcus CL, Keens TG et al. Obstructive sleep apnea in children with Down syndrome.Pediatrics 1991; 88(1):132-9.
10. Lipton AJ, Gozal D. Treatment of obstructive sleep apnea in children: do we really know how? Sleep Medicine Reviews 2003; 7 (1):61-80.
11. Cebeci AN, Güven A, Yıldız M. Profile of Hypothyroidism in Down's Syndrome. J Clin Res Pediatr Endocrinol. 2013 Jun; 5(2): 116–20.
12. Shott SR, Amin R, Chini B, Heubi C, Hotze S, Akers R. Obstructive Sleep Apnea: Should All Children with Down syndrome be tested? Archives of Otolaryngology Head and Neck Surgery 2006; 132: 432-6.

Correspondence to:

Giorgiana Brad
University of Medicine and Pharmacy "Victor Babes"
2 Eftimie Murgu,
Timisoara,
Romania,
E-mail: giorgiana.brad@gmail.com

UP-TO-DATE CLASSIFICATION AND TREATMENT IN OSTEOGENESIS IMPERFECTA

Camelia Gliga[1], Ionela Pașcanu[1], Marius Gliga[2], Maximilian Gliga[3]

Abstract

The term of osteogenesis imperfecta (OI) includes a heterogeneous group of genetic disorders of connective tissue and has as the main form of expression recurrent fractures, skeletal fragility and deformity. OI is one of the most common skeletal dysplasias. The disease has an etiology related directly or indirectly to type I collagen, the most important protein of the bone extracellular matrix. The diagnosis of OI is based on history and clinical examination associated with genetic analyses, imaging and laboratory investigations. OI is a disorder which has many clinical manifestations, some of these are present only in certain types of the disease, some characteristics being age-dependent. There is no cure for OI. Treatment is aimed at increasing bone strenght to prevent fracture, the surgical correction of deformity, minimizing pain and maximizing mobility and independent function.

Key words: osteogenesis imperfecta, COL1A1, COL1A2, pamidronate, classification

Etiology and classification

The term of osteogenesis imperfecta (OI) includes a heterogeneous group of genetic disorders of connective tissue and has as the main form of expression recurrent fractures, skeletal fragility and deformity [1]. OI is one of the most common skeletal dysplasias.

The disease has an etiology related directly or indirectly to type I collagen, the most important protein of the bone extracellular matrix [2]. In most cases, 90%(classical types), OI is caused by a autosomal dominant mutation in the COL1A1 gene on chromosome 17 or the COL1A2 gene on chromosome 7, that encode type I collagen [3]. In 10 percent of cases it is believed that OI (non-classical types) is caused by recessive mutations in other genes, that encode proteins from collagen structure: prolyl 3-hydroxylase (P3H1, encoded by the LEPRE1 gene), cartilage-associated protein (CRTAP gene) and peptidyl-prolyl isomerase cyclophilin B (CypB, encoded by the Ppib gene). Sometimes, OI is not inherited but is caused by a gene mutation occurred spontaneously at childhood (de novo mutation). In this case none of parents is affected. Changes in the collagen can be qualitative (defective collagen structure) or quantitative (insufficient amount of collagen).

The classic clinical forms of OI comprise Lobstein's type and Vrolik's type. The first has a variable symptomatology, with a greater or lesser degree of deformity and onset of fractures during growth and adulthood. The second is a severe form that is observable from birth, with frequent intrauterine fractures and a high mortality rate [4].

Because of the clinical variability in OI, more authors [5] have attempted to classify this disease. First classification, which is still used today, was introduced by the Australian physician David Sillence (the "Sillence classification") in 1979 [6] and classifies the disease in 4 types (I-IV). This was based on clinical and radiological findings of OI. In 2004 the Lancet published a new classification: "expanded Sillence classification" which recognizes seven types of OI (I-VII) and in 2007 was proposed an additional type VIII (table 1).

Table 1. Sillence Classification expanded with OI VIII type as proposed by Rauch (2004) and Cabral (2007) [5].

OI type Sillence classification expanded	Clinical severity	Mutated gene	Mode of inheritance
I	Mild-non deforming	COL1A1/2	AD
II	Perinatal lethal	COL1A1/2	AD
III	Severely deforming	COL1A1/2	AD
IV	Moderately deforming	COL1A1/2	AD
V	Moderately deforming	Unknown	AD
VI	Moderately to severely deforming	Unknown	AR
VII	Moderately deforming	CRTAP	AR
VIII	Severely deforming to perinatal lethal	LEPRE1	AR

[1]Clinic of Endocrinology Targu Mures
[2]Clinic of Obstetrics and Gynecology Targu Mures,
[3]Student of University of Medicine and Pharmacy Targu Mures
E-mail: gliga.camelia@gmail.com, iopascanu@gmail.com, m11gliga@yahoo.com, maxtenn111@yahoo.com

In recent years, a molecular genetic classification of OI contains 12 types that display either autosomal -dominant or autosomal-recessive patterns of inheritance and exhibit broad variations in clinical severity [7].

Type I of OI is mild as severity, without progressive deformity, type II is lethal and type III is severe with progressive bony deformity and characteristic facies. Type IV is less well defined and has phenotypic range between types I and III. All of these types are associated with bone fragility, kynetic development delay and growth retardation of varying degrees, depending on the severity of the disease.

Diagnosis

The diagnosis of OI is based on history and clinical examination associated with genetic analyses, imaging and laboratory investigations. It may be difficult to make a clinical diagnosis of the milder forms of OI in infancy and childhood. Some patients have a family history of osteogenesis imperfecta, but most cases are due to new mutations [8]. The most important dates in the history and physical examination of patients with OI include: a detailed family history of bone disease, the presence of fractures detected in utero or in the neonatal period; the nature, chronology, and outcome of subsequent fractures; growth velocity, current height and skeletal proportions; the presence and progression of bone deformity. The distinction between mild, moderate, and severe types of disease is based on the number of fractures, the degree of bones deformity and growth impairment, and the age at which the disease is first recognized.

Clinical Features

OI is a disorder which has many clinical manifestations, some of these are present only in certain types of the disease, some characteristics being age-dependent. The clinical features of OI, in addition to fractures after minor trauma, may include the following:

- The blue sclerae (50 percent of cases).
- Dentinogenesis imperfecta, characterized by transparent, discolored, and fragile teeth that fracture easily (50 percent of people with OI, particularly in those with the severe forms).
- Bone malformations: pectus carinatum, pectus excavatum, abnormal rib shape, curving of the long bones, vertebral compressions, scoliosis, kyphosis.
- Osteopenia or osteoporosis (x ray or bone density tests-DEXA).
- The head circumference may be greater than average and the head may appear large relative to the person's small body.
- A triangular facial shape is characteristic in the more severe forms.
- The fontanels may close later than usual.
- Hearing loss which starts in the young adult (about 50% of patients with type I OI have deafness by age 40 years).
- The body may be disproportional.
- The joints may be lax and unstable and the feet may be flat.
- Wormian bones are present in the skull (60 percent of cases).
- Children have decreased muscle mass and associated muscle weakness.
- Motor development may be delayed due to fractures and muscle hypotonia.
- The intellect is normal.
- In some cases exuberant callus formation may occur, which usually follows a fracture or a surgical procedure (OI Type V).

Investigations

OI is usually a clinical diagnosis but performing additional investigations may provide useful information in cases where there is some uncertainty and will often help guiding the management [8].

Prenatal testing is possible and indicated for high risk pregnanacies (if the mutation has been identified at a relative), being made through the analyse of the collagen synthesis from the fetal cells obtained at 12 weeks villi sample or amniocentesis. Prenatal screening ultrasonography, performed during the second trimester, in severe cases of OI, may show: bowing of long bones, fractures, limb shortening, and decreased skull echogenicity.

Bone radiological investigations may show: osteopenia (low bone density) or osteoporosis, fractures (new, subclinical, or old-healing), bowing of the long bones, vertebral compressions, and wormian bones in the skull sutures (in 60% of patients with OI).

DEXA (Dual Energy X-ray Absorptiometry) provides information about bone quantity, not quality. A low mineral density might be prognostic for a predisposition to fracture. Bone mineral density may be lower than normal in people with any type of OI. At children Z score is used for the interpretation of results [9].

Bone Biopsy of the iliac bone can identify all types of OI. Unfortunately a bone biopsy is a invasive procedure, requiring general anesthesia and specially trained personnel for processing the sample and read the slides. A child must weigh at least 10 kilograms to be a candidate for the procedure. A bone biopsy may be obtained during orthopaedic surgery.

Laboratory testing (for the dominant and recessive forms of OI):

• Collagen molecular testing - a DNA-based analysis of COL1A1 and COL1A2 genes from a blood or saliva sample,

• Collagen biochemical testing - a protein-based analysis of cultured fibroblasts from a skin sample,

• Separate studies that utilize a skin biopsy and sequencing of the genes for cartilageassociated protein (CRTAP) and prolyl 3-hydroxylase (LEPRE1) to test for the recessive forms of OI (when the molecular and biochemical testing are normal in a child with clinically diagnosed OI)

Differential Diagnosis

Other medical conditions that share some of the same clinical signs as OI should be excludend. Among them: hypophosphatasia, juvenile Paget's disease, rickets, idiopathic juvenile osteoporosis, some inherited defects in

vitamin D metabolism, Cushing's disease, and calcium deficiency and malabsorption. Ehlers-Danlos syndrome types VIIA and VIIB, which are characterized by lax ligaments and loose joints, can also predispose a person to fractures.

Treatment

There is no cure for OI. Treatment is aimed at increasing bone strenght to prevent fracture, the surgical correction of deformity, minimizing pain and maximizing mobility and independent function. Treatment strategy is multidisciplinary, involving a team of endocrinologist, orthopedist, surgeons, psychiatrists, dentinsts etc. Methods of treatment currently prescribed include the following:

- behavioral and lifestyle modifications to avoid situations that may cause a fracture,
- orthopaedic surgery,
- scoliosis management,
- physical rehabilitation through physiotherapy and hydrotherapy (strengthen muscles and improve mobility in a gentle manner) [10],
- adaptive equipment and ambulation aids (wheelchairs, braces, and other aids),
- weight management,
- pain management,
- pharmacological treatment with bisphosphonates (a 'standard care' for children with OI) ,
- treatment with GH.

Pharmacological treatment

Treatment with intravenous bisphosphonates was first suggested as treatment to improve bone fragility in children with severe OI in 1987 and it has rapidly become a standard of care [11]. When administered either orally or parenterally, bisphosphonates rapid bond to hydroxyapatite crystals in bone and, by decreasing osteoclast activity and number, inhibit bone resorption and reduce bone turnover [12]. Another important effect of this treatment is the improvement in bone pain, well-being and longitudinal growth, increase in vertebral and long bone mass with a reduced fracture rate [13].

Cyclic intravenous treatment with pamidronate is the only treatment authorized in many countries for use in children with OI. There is no clear consensus on dose, frequency of dosing, dose adjustment and when to discontinue treatment in OI [13, 14]. The protocol used in Romania recommends the beginning of the treatment at children over 2 years old with a dose of 1 mg/kg/day 3 consecutive days, administered with a intravenuos slow infusion. The cure is repeated every 3 months for 2-4 years [13]. Data from the literature suggest that the greatest gain in the bone density is obtained after 2-4 years of therapy. At any rate, in the opinion of many specialists, it does not seem advantageous to stop bisphosphonates treatment in growing children. Pamidronate is a member of the bisphosphonate family of drugs, which are potent antiresorptive agent. He interferes with the mevalonate pathway of cholesterol biosynthesis in osteoclasts, inhibiting the function of these cells but not usually leading to apoptosis, as was believed previously. Rehabilitative therapy together with adequate Ca and P intake during this treatment could be another way to prevent fractures caused by bone fragility.

A hormone with a favorable effect on bone metabolism is GH who has a positive effect on bone growth and bone turnover by stimulating osteoblasts, collagen synthesis, and longitudinal bone growth [15]. In osteoblast cultures, GH has also shown a positive action on collagen metabolism , by stimulating the expression of insulin-like growth factor 1 (IGF1) and IGF-binding protein 3 (IGFBP-3), which in turn regulates the synthesis of type I collagen. However, there is limited literature data regarding recombinant human GH (rGH) experience in OI. At this time, GH is not found in the standard treatment guidelines in OI [12].

Other therapeutic options were [13]:

- Human recombinant PTH (Teriparatid) which has not been aproved for children use because of the osteosarcoma risk.
- Bone marrow transplant: the hematopoietic bone marrow contains osteoblast precursors, but for supporting the fibroblast production a very large quantity is needed; also the immunosupresive therapy required for every transplant can be itself a source of bone distruction.
- The gene therapy is nowadays in experimental state on animals; its purpose is to block a mutant allele at the COL1 gene and not to interfere with the expression of a normal allele (prevents the translation of a gene responsable for a collagen deffect), so a severe form of OI can be transformed in a moderate form.

Orthopaedic surgery

- The goals of orthopaedic treatment include fracture care and prevention or correction of bone deformities.
- The use of bracing, splinting, and orthotic supports have an important role in treatment.
- Insertion of intramedullary rods or nails (typically in the lower limbs) is the commonest surgical procedure in OI [8]. Indications include prevention of recurrent fractures and correction of deformity (with osteotomies). The commonest indication for spinal surgery is prevention of scoliosis progression. Details of management depend on the severity of the scoliosis and the age of the patient.

Rehabilitation, physical therapy, occupational therapy,nutrition and physical activity

- Most children with OI benefit from physical activity programs. They should include muscle strengthening, aerobic conditioning, and, when possible, protected ambulation.
- Positioning is important to avoid contracture and malformation. It is important not to leave a child with OI in a fixed position, either recumbent or sitting, for long periods.
- Postfracture therapy is necessary to reduce the effects of immobilization on bone density and strength.
- The goal of physical therapy should be to improve function, fitness, and independent movement [10].
- The nutrition goals for individuals with OI are the same as for any individual: to achieve optimal health by taking in adequate kcalories to achieve and maintain a healthy weight [16].

Conclusions

OI is a genetic connective tissue disorder that involves multiple organ systems, can affect an individual's function as they age. Most physicians will see very few people with this disorder during their careers. Despite the need for multiple interventions, adequate treatment of patients with OI can provide acceptable functional outcomes.

References

1. Tim Cundy, Recent Advances in Osteogenesis Imperfecta, Calcif. Tissue. Int. 2012 Jun; 90(6):439-49
2. Warman ML, Cormier-Daire V, Hall C, Krakow D, Lachman R, LeMerrer M, Mortier G, Mundlos S, Nishimura G, Rimoin DL, Robertson S, Savarirayan R, Sillence D, Spranger J, Unger S, Zabel B, Superti-Furga A, Nosology and classification of genetic skeletal disorders: 2010 revision. Am. J. Med. Genet. 155A:943–968.
3. Joan C. Marini, Angela R. Blissett, New Genes in Bone Development: What's New in Osteogenesis Imperfecta, J. Clin. Endocrinol. Metab, August 2013, 98(8):3095–3103.
4. R.J. Escribano Reya, J. Duart-Clementeb, O. Martínez de la Llanac, J.L. Beguiristáin Gúrpided, Osteogenesis imperfecta: Treatment and results of a case series, Rev. Esp. Cir. Ortop. Traumatol. 2014;58(2):114-119.
5. F.S. Van Dijk a, G. Pals a, R.R. Van Rijn b, P.G.J. Nikkels c, J.M. Cobben d, Classification of Osteogenesis Imperfecta revisited, European Journal of Medical Genetics 53 (2010) 1-5
6. D. Sillence, K. Barlow, A. Garber, J. Hall, D. Rimoin, Osteogenesis imperfecta type II delineation of the phenotype with reference to genetic heterogeneity. Am. J. Med. Genet. 17 (1984) 407-423.
7. Eugenia R. Valadaresa, Túlio B. Carneiroa, Paula M. Santosb, Ana Cristina Oliveirab, Bernhard Zabelc. What is new in genetics and osteogenesis imperfecta classification?, J. Pediatr. (Rio J). 2014;90(6): 536-541.
8. Paul Arundel, Osteogenesis imperfecta: Paediatrics and child health, 2015 Elsevier: 1-6.
9. Gordon CM, Leonard MB, Zemel BS, Densitometry ISfC. Pediatric Position Development Conference: executive summary and reflections. J. Clin. Densitom 2014; 17: 219-24.
10. Sabina Macoveia, Radu-Ștefan Mandachea, Osteogenesis Imperfecta and its Consequences on the Disabled Children's Capacity for Effort and Movement, Procedia - Social and Behavioral Sciences 117 (2014) 67 – 73.
11. Devogelaer JP, Malghem J, Maldague B, Nagant de Deuxchaines C (1987), Radiological manifestations of bisphosphonate treatment with APD in a child suffering from osteogenesis imperfecta. Skel. Radiol. 16:360–363.
12. Franco Antoniazzi, Elena Monti, Giacomo Venturi, Roberto Franceschi, Francesco Doro, Davide Gatti, Giorgio Zamboni, Luciano Tato, GH in combination with bisphosphonate treatment in osteogenesis imperfecta, European Journal of Endocrinology (2010) 163 479–487.
13. Rauch F, Glorieux FH (2004) Osteogenesis imperfecta. Lancet 363:1377–1385
14. Salehpour S, Tavakkoli S. Cyclic pamidronate therapy in children with osteogenesis imperfecta. J. Pediatr.Endocrinol. Metab. 2010 JanFeb. 23(12):73-80.

Correspondence to:

Dr. Ionela Pascanu
Spitalul Clinic Județean Targu Mures
Compartiment Endocrinologie
Str. Gheorghe Marinescu nr. 38
Email: iopascanu@gmail.com

FEATURES OF THE ENDOCRINE-METABOLIC PLURIMALFORMATIVE SYNDROME

Mariana Boia[1], Aniko Manea[1], Oana Bilav[2]

Abstract

Introduction: Inherited metabolic disorders refer to different types of medical conditions that result in metabolism problems. They involve great complexity of the underlying pathophysiology, biochemical workup, and analysis and have complicated therapeutic options for management. They are disorders of great importance to physicians treating newborns because rapid diagnosis and appropriate treatment of these conditions are directly related to the patient's outcome in terms of mortality and morbidity. Some metabolic disorders can be diagnosed by routine screening tests done at birth, others are identified only after a child or adult shows symptoms of a disorder.A wide range of tests are required for the diagnosis of inborn errors of metabolism and the level of clinical and biochemical experience required is often substantial. There are hundreds of different genetic metabolic disorders, and their symptoms, treatments, and prognosis vary widely.

Case presentation: The 4 month old newborn baby boy, admitted to the IC Premature Children's ward at "Louis Turcanu" Emergency Hospital, diagnosed ventriculomegaly and agenesis of corpus callosum, seizure type EEG is investigated to establish the etiology of diseases, *is suspected* for an Inherited *Metabolic Disease*.

Conclusions: Molecular genetic analysis has become a necessity due to the numerous clinical forms existing in the specialty literature. Confirmation of the diagnosis will allow the appreciation of the prognosis and of the measures that need to be taken in order to improve the child's quality of life. It requires multidisciplinary monitoring (pediatrician, endocrinologist, geneticist, neuropsychiatrist).

Key words: metabolic disease, genetics, ventriculomegaly, agenesis of corpus callosum

Introduction

Though individually congenital metabolic diseases are relatively rare conditions, as a group there is a vast and diverse collection of diseases that are a significant cause of morbidity and mortality worldwide. Onset is usually in the neonatal period and childhood but can occur at any time, even in adulthood. The diagnosis does not require extensive knowledge of biochemical pathways or individual metabolic diseases. An understanding of the major clinical manifestations of congenital metabolic defects provides the basis for knowing when to consider the diagnosis. There may be several inborn errors of metabolism that are entirely incompatible with life and lead to intrauterine fetal death.

Because of the many different errors of metabolism diagnostic tests are used for screening.

Inborn errors of metabolism can affect any organ or usually affects multiple organ systems, resulting in increased mortality due to acute or chronic organ dysfunction.

In the strictest sense, acquired metabolic disorders were defined using biochemical bases. Broad categories include carbohydrate metabolism disorders, disorders of amino acid metabolism, organic acidaemia, lysosomal storage diseases, disorders of fatty acid metabolism and mitochondrial disorders. Most, but not all, of these conditions are associated with some neurological sequelae.

For patients with inborn suspected or known metabolism defects, treatment success depends on the prompt establishment of therapy that aims the metabolic stabilization.

Case presentation

The child aged 4 months, male, from undispensarised pregnancy, born at term, in breech position, birth weight 2900g, PC = 33cm, PT = 31cm, PA = 30cm, waist = 49cm, APGAR score= 7.

The current general clinical examination revealed a particular phenotype with trigonocephaly with microcephaly, epicanthic fold, 36.5 cm head circumference (<-2 SD), pointlike anterior fontanelle, asymmetricears, ogive vault, chest with flared bases, Ist grade left parasternal systolic murmur, hypotonia, microclamped external genitalia (2 cm), microplasic scrotum with suturelike median strip bilateral cryptorchidism.

Besides the usual biological investigations that were within normal limits, the following were also collected (Tabel 1):

[1]University of Medicine and Pharmacology ''Victor Babes'', Neonatology, Timisoara, Romania
[2]Emergency Children Hospital "Louis Turcanu", Neonatology, Timisoara, Romania
E-mail: marianaboia@yahoo.com, aniko1807989@yahoo.com, oanabilav@yahoo.com

Tab.1 - laboratory investigation used for diagnostic.

Lactic acid	4,2 mmol/L ↑
Plasma Amoniemia	943 µg/L ↑
Cortisol	199,5 nmol/L
Testosterone	0,12 ng/ml
FSH	0,503 mUI/ml
LH	< 0,100 mUI/ml ↓
DHEAS	< 15 µg/dl
Anti MullerianHormone	22,690 ng/ml
Ac anti HBs	< 2 U/L
Ac anti HCV	0,096 U/L
ToxoIgG	< 0,130 UI/ml
ToxoIgM	0,229 UI/ml
CMV IgG	279,5 U/ml
CMV IgM	0,268 U/ml
VDRL (qualitative)	Negative
TPHA	Negative

Karyotype: 46, XY - without structural changes

Transfontanelar ultrasonography: agenesis of the corpus callosum with bilateral stabilized ventriculomegaly (Figure 1).

CT: brain substance without supra or infratentorial density changes. Ectasia up to 19 mm of the occipital horn of the left lateral ventricle.Lack of viewing the corpus callosum.Ventricle III 3 mm, without deviation from the midline of the lateral ventricular system. Mastoid antre without collections. Cranial sutures present.

Cardiac Ultrasound: patent foramen ovale.

Renal ultrasound: without pathological sonographic changes.

Abdominal and pelvic ultrasound: unviewed testicle.

EEG: convulsive trail with theta and delta waves and T "waves" discharges (Figure 2).

Indirect ophthalmoscope and FAO: no pathological changes.

The clinical status of the infant is stable, administering anticonvulsant therapy due to the changes observed in the EEG.

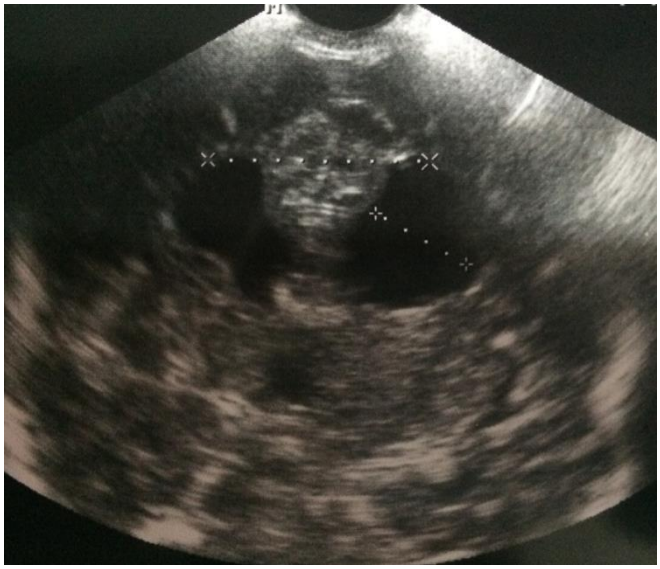

Figure 1: Coronal image - bilateral ventriculomegaly.

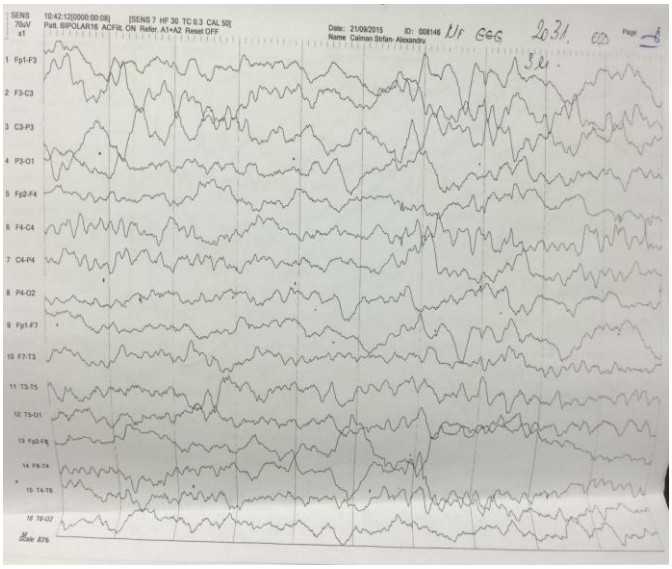

Figure 2: A temporal segment of EEG with convulsive trail with theta and delta waves and T "waves" discharges.

Disscutions

Nearly every metabolic disease has several forms that vary depending on the age at which debuted, clinical severity and often legacy mode.

The overall incidence and frequency of individual diseases varies by racial and ethnic composition of the population and the scale of screening programs. [1]

Asymptomatic newborns with positive screening tests results for congenital metabolic diseases, may require

evaluation of energy, including confirmatory testing and, where appropriate, initiation of specific disease management.

Inborn errors of metabolism are rare as individual entities, but together they create a diverse group of diseases known so far a total of more than 700 diseases and conditions. [2], [3] These disorders have genetic origin, mode of transmission autosomal recessive in general and, in a few cases, X-linked recessive. [4]

The complexity of the case presented makes it difficult to establish a precise diagnosis. Data from clinical and paraclinical advocates for a genetic error of metabolism - possible TMEM 70 gene mutation.

According to Honzík T et deficit ATP synthase mutation TMEM70 should be considered in the diagnosis and management of newborns with critically ill and early neonatal-onset muscle hypotonia, hypertrophic cardiomyopathy and hypospadias in boys, accompanied by lactic acidosis, hyperammonemia and 3-metilglutaconic acidemia. In over 76% to 92% of cases there was hypertrophic cardiomyopathy, severe muscle weakness, lactic acidosis and hyperammonemia. Increased lactic acid and 3-metilglutaconic acid were observed in all cases studied by them. However, the severity of the phenotype can vary significantly. The pathology is frequent in the Roma population and molecular analysis of TMEM 70 gene is enough for a diagnosis, without the muscle biopsy being necessary. [5]

Brain imaging is helpful in determining brain injuries. In a study that included 48 patients in which brain CT or MRI was performed, in 19 cases, the most common findings were: white matter changes on eight children, as further specified in three cases as hypomyelination and delayed myelination into one of them, periventricular cysts were observed in four cases, and agenesis and hypoplasia of the corpus callosum in four cases. [6]

Although the first patients with TMEM70 deficit were diagnosed due to low ATP synthase activity in histochemical analysis of muscle biopsies, [7] the invasive procedures can be avoided by analysis of molecular genetics TMEM 70 in clinical suspicion children. [8]

In a study that aimed to determine the prevalence of developmental defects of the corpus callosum in patients with genetic metabolic disorders was showed that all 19 patients diagnosed with inborn errors of metabolism showed varying degrees of hypoplasia, agenesis or partial body callosum. Abnormalities associated with central nervous system included ventricular morphology defects in 18/19 (94.7%), ventriculomegaly in 11/19 (63.1%) extraaxial increase of cerebrospinal fluid in 11/19 (57.9%), changes in gray matter (neuronal migration defects and porencephaly) in 9/19 (47.3%), changes in white matter in 12/19 (63.1%) and posterior fossa and cerebellum abnormalities in 12 / 19 (63.1%). The authors emphasized that patients with inborn errors of metabolism, dysgenesis of the corpus callosum serves as a marker for other developmental defects of the nervous system. [9]

In our case the absence of the corpus callosum was associated with up to 19 mm ectasia occipital horn of the lateral ventricle and left ventricle III 3 mm on MRI images, and transfontanelar ultrasound detects agenesis of corpus callosum with bilateral stabilizedventriculomegaly.

Various mechanisms have been proposed to explain abnormal brain development in inborn errors of metabolism: the toxic intrauterine environment or energy deficit, modifying the content and function of membranes or disruption of normal gene expression intrauterine responsible for morphogenesis. The recognition of metabolic disorders as the cause of malformation of the brain has implications for both patient care and genetic counseling to prevent recurrence in subsequent pregnancies. [10]

Many of inborn errors of metabolism, including urea cycle defects, organic acidaemia metabolism disorders and certain amino acids are present in children with symptoms of acute or chronic metabolic encephalopathy. Typical symptoms include lethargy, loss of appetite, apnea or tachypneaand recurrent vomiting. Metabolic acidosis and / or hyperammonemia are found in many of these conditions.Therefore, appropriate laboratory tests for metabolic disorders should be performed in any child exhibiting these manifestations. Although the first intention, sepsis should be considered in a newborn with these symptoms, the congenital metabolic defects should always be a part in the differential diagnosis, especially in a baby to term with no specific risk factors. [11]

Although the clinical picture may vary as metabolic disease progresses, progressive tone abnormalities may occur (hypotonia, hypertonia), changes in posture (opistotonus), apnea. [12] Elevated plasmatic levels of ammonia, metabolic acidosis and hypoglycemia if present, are suggestive of congenital metabolic disorders. [13]

Evolution of genetic diseases can be acuteand can deteriorate within hours, intermittent and episodic decompensation or asymptomatic intervals with insidious onset and slow degeneration over decades, sometimes reaching a debilitating level. They usually create an aesthetic, sensory, motor or mental handicap.

Without treatment, innate metabolic disease will cause permanent damage, severe mental retardation is the most common complication. Early detection allows early intervention which will have a key role in preventing health and developmental problems, which will allow the child to have a normal life and be integrated into society.

With the advancement of enzyme replacement therapy and, ultimately gene therapy, some inborn diseases that can not be treated today will become treatable in the future.

Conclusions

Molecular genetic analysis has become a necessity due to the numerous clinical forms existing in the specialty literature that can not be diagnosed by common means of disposal.

To confirm the diagnosis are necessary clinical knowledge, indication genetic and multilateral approach while knowing that there are several cases that require more accurate framing than theearly diagnosed cases.

Confirmation of the diagnosis will allow the appreciation of the prognosis and ofthe measures that need to be taken in order to improve the child's quality of life.

Evolving case requires multidisciplinary monitoring (pediatrician, endocrinologist, geneticist, neuropsychiatrist).

References

1. Huang X Dr, Yang L Dr, Tong F Dr, Yang R Dr, Zhao Z Prof. Screening for inborn errors of metabolism in high-risk children: a 3-year pilot study in Zhejiang Province, China. BMC Pediatr.2012 Feb 24. 12(1):18.
2. H. M. Sinclair, 1962, Historical aspects of inborn errors of metabolism. Magdalen College, Oxford, Department of Biochemistry, University of Oxford, p. 5.
3. Watson J.D., 1970; Molecular Biology Of The Gene. Second Edition, W. A. Benjamin inc. New York, p. 46-47.
4. Maximilian C. - Geneticaumana. Ed.St. siEnciclopedica.Bucuresti, 1982; p. 131.
5. Honzík T, Tesarová M, Mayr JA, Hansíková H, Jesina P, Bodamer O, Koch J, Magner M, Freisinger P, Huemer M, Kostková O, van Coster R, Kmoch S, Houstêk J, Sperl W, Zeman J. - Mitochondrial encephalocardio-myopathy with early neonatal onset due to TMEM70 mutation. Arch Dis Child. 2010 Apr; 95(4):296-301.
6. Martin Magner, VeronikaDvorakova, MarketaTesarova, Stella Mazurova, Hana Hansikova, Martin Zahorec, Katarina Brennerova - TMEM70 deficiency: long-term outcome of 48 patients, J Inherit Metab Dis DOI 10.1007/s10545-014-9774-8
7. Sperl W, Jesina P, ZemanJetal Deficiency of mitochondrial ATP synthase of nuclear origin. 2006 NeuromusculDisord 16:821–829
8. Honzik T, Tesarova M, Magner M - Neonatal onset of mitochondrial disorders in 129 patients: clinical and laboratory characteristics and a new approach to diagnosis. J Inherit Metab Dis (2012) 35:749–759
9. Prasad AN1, Bunzeluk K, Prasad C, Chodirker BN, Magnus KG, Greenberg CR - Agenesis of the corpus callosum and cerebral anomalies in inborn errors of metabolism. CongenitAnom (Kyoto). 2007 Dec 47(4):125-35.
10. AndreeaNissenkorn, Marina Michelson, Bruria Ben-Zeev, Tally Lerman–Sagie - Inborn errors of metabolism A cause of abnormal brain development. Neurology May 22, 2001 vol. 56 no. 10 1265-1272
11. Barbara K. Burton - Inborn Errors of Metabolism in Infancy: A Guide to Diagnosis. Pediatrics Vol. 102 No. 6 December 1, 1998 pp. e69
12. Clarke JT. - A Clinical Guide to Inherited Metabolic Diseases. 2nd ed. New York: Cambridge University Press, 2002
13. Raghuveer, Talkad S., UttamGarg, and William D. Graf. "Inborn errors of metabolism in infancy and early childhood: an update." Am Fam Physician 73.11 (2006): 1981-90

Correspondence to:

Aniko Manea
"Victor Babes" University of Medicine and Pharmacy,
Department of Pediatrics
2 Eftimie Murgu 300041
Timisoara, Romania
E-mail: aniko1807989@yahoo.com

MANAGEMENT OF CRANIPHARINGIOMAS IN CHILHOOD

Otilia Marginean[1,2], Giorgiana Brad[1,2], Ramona Stroescu[1,2], Daniela Chiru[1,2], Oana Belei[1,2], Olariu Laura[1,2], Cristun Lucian Ioan[1], Marioara Boia[1]

Abstract

A 7 year old patient known from his medical history with visual impairment from the age 2 years and 6 months, which have progressed once the child began school. Careful examination revealed the presence of a tumor formation with selar location, which proved to be craniopharyngioma. Postoperative evolution was relatively good, but a redoubtable complication appeared, namely diencephalic obesity.

Key words: craniopharingiomas, child

Introduction

Craniopharyngioma is a partially cystic embryogenetic malformation localized sellar or parasellar. The incidence is 0.5-2 new cases / year / 1000000 in the general population; 30-50% of these cases are found in children (1). Central Brain Tumor Register (USA) 0.13 / 100,000 with a peek at 5-9 years with incidence 0.2 / 100,000 cases. In terms of pathogenesis there are two types: adamantinomatous and papillary. The first form implies the neoplastic transformation of the embryonic squamous cell involving the craniopharingeal duct which connects Rathke's cleft with the stomodeum. Trough the proliferation and rotation process, Rathke's cleft is contributing in the formation of the adenohypophysar cells (3). This origin explains the extension to the suprasellar region. Clinic, symptoms are nonspecific, most often occur as a nonspecific headache, visual abnormalities, severe short stature, polyuria, polydipsia and sometimes weight gain. Rational approach is surgical removal by transsphenoidal or transcranial approach depending on the location and extension and irradiation at high age groups - teenagers, adults (conventional radiotherapy, intracavitary irradiation). Reportedly tumor recurrence is more common in patients whose onset has occurred under the age of 5 years. No gender discrepancies in terms of the frequency of relapses have been noticed. Recorded post-surgical after-effects are pituitary hormone deficiency; some impairments are present before surgery with postsurgical emphasis, requiring replacement on that line. If tumors are very large and affects the optic chiasm it is likely to experience post-surgical visual disturbances and even amblyopia. Hypothalamic dysfunction as sleep disorders and circadian rhythm abnormalities and obesity are also known to appear (3). Mortality in patients with craniopharyngioma is 4 times higher than in the general population. As opposed to craniopharyngioma with an onset in adulthood, the onset in childhood can lead to hydrocephalus in patients less than 5 years old. Recent studies report decreased cognitive performances in pediatric patients with large tumors that require resection (5).

Case presentation

SRL, 7-year old patient with visual disorders onset in September 2014 with the beginning of the school year. The ophthalmologic examination performed in this period highlights dyschromatopsia (already known from the age of 2 years and 6 months) and decreased visual acuity with gradual progression from AVOD = 80% and AVOS = 30% (September 2014) to the AVOD = 10% and AVOS = 30% in November. In december, to exclude a possible damage to the eye, a cranial MRI investigation is performed and revealed a sellar and suprasellar tumor with dimensions of 33/35/27 mm. Physical exam reveals a height of 111.5 cm, height of age : HA = 119.87+/- 5.18 (SDS = -2.34) - according Prader scale, W = 20 kg , weight of age :VH = 18.66+/-2.53, harmonic. External genitalia, well configured, stage 1 puberty (according Prader scale). The patient does not present cephalalgic syndrome, polyuria or polydipsia. RX Vo = 3.6 - 4 years. Biochemical investigations highlights central hypothyroidism TSH = 1.69 mmol / nl, FT4 = 7.29 pmol / L (low) and hypocortisolism (7.25 umol/dl). IGF1 = 39.56 ng / ml. the child was sent to chirurgical department. Preoperative MRI revealed in March 2015 a voluminous expansive process increased in size compared to previous examination 41.5 / 32.5 / 29 cm, developed into the suprasellar region, with a compressing effect on the optic chiasm and ventricle III, with intraemispheric expansion, clear contour, irregular, polilobulated, suggestive of craniopharyngioma, well vascularized and forming adherences to the infundibul and sellar diaphragm (Fig No. 1).

[1]„Victor Babes" University of Medicine and Pharmacy, Timisoara, Romania
[2]„Louis Turcanu" Emergency Children Hospital Timisoara, Romania
[3]University of Medicine and Pharmacy, Targu-Mures, Romania
E-mail: omarginean@ymail.com, giorgiana.brad@gmail.com, ramona.giurescu@gmail.com, dani.chiru@yahoo.com, belei.oana@gmail.com, tunealaura@yahoo.com, mailto:lucian.cristun@yahoo.com, marianaboia@yahoo.com

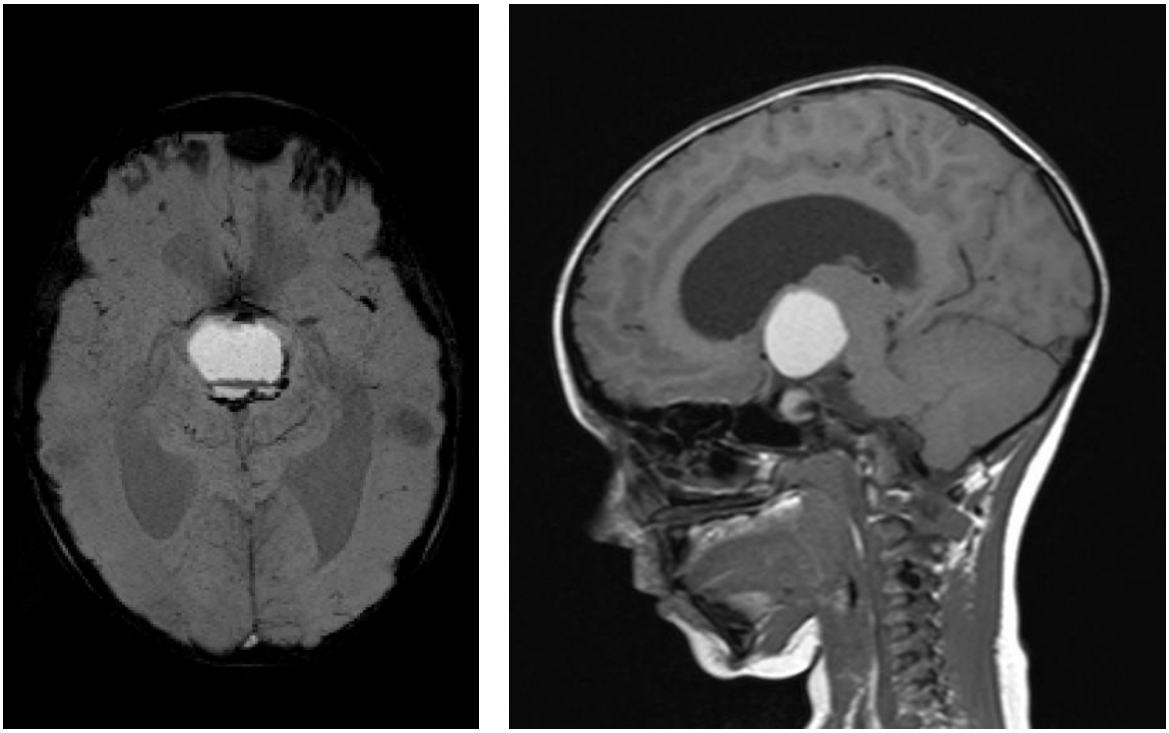

Fig . 1. SRL - MRI before surgery.

The solid portion of the tumor is poorly represented with yellowish microcalcifications. The complete resection of the tumor was achieved; the resected piece is sent for histology and immunohistochemistry. Microscopic findings revealed squamous epithelial cell proliferation in nests and trabeculae with peripheral arrangement in polisade, central stellate cells in an edematous fibrovascular stroma and cystic degeneration; ”wet keratin” deposits, microcalcifications, granular cholesterol deposits and polymorph inflammatory infiltrate; adjacent brain tissue with reactive astrocytal gliosis.

The conclusion of the histopathological examination is adamantinomatos craniopharyngioma. Preoperative, the patient received Euthyrox 25 ug, 1/2 cp / day po 30 minutes before a meal and Hydrocortisone powder 7.5 mg, 2.5 mg every 8 hours (8-14-22). Biological investigations revealed moderate cytolysis ALT = 64 U / l (VN <39 U / l) cholesterol = 7.65 mmol / l, increased (VN <5.2 mmol / L), LDL cholesterol = 5.13 mmol / l (VN = 0-3.35 mmol / l), increased total lipids = 8.33 g / l (VN = 5-8 g / l) increased dose; cortisol = 22.91 (VN = 171-536), low FT3 = 2.30 pmol / l (VN = 4.1-7.9 pmol / l) decreased. The rapid weight gain of 1.5 kg in two months post surgical intervention, led us to investigate the metabolism of carbohydrates: glucose = 4.24 (VN), insulinemia = 2.13 uiu / mL, HOMA = 0.4, C peptide= 0.66. The substitution were Hydrocortisone 7.5-5-5 mg /day ,Euthyrox 1-0-0 hp 25 hp ug / day and Minirin Melt in the same dosage; at the same time a hypocaloric hypoglucidic and hypolipidic diet was established. Fours months after the surgery, a performed neurosurgical control indicated MRI; It highlights: pterion bone flap law; little fluid accumulation bilateraly, fronto-parietal subdural pericerebral with hyper T2 and T1 hyposignal, well-defined with hygroma aspect, with maximum thickness of about 10 mm associating minimal gadolinophyl thickening of 3 mm of the convexitar meninges; no pathological locoregional contrast prize, sellar or suprasellary, without MRI visible signs of tumor rest; the widend aspect of the turkish saddle, chiasm tank, suprasellar region, supraoptic recess respectively interpeduncular fossa; symmetrical ventricular system on the midline, with increased lateral ventricle size, relatively unchanged to postoperative examination; midline structures in normal position. The substitution treatment is continued, but the auxological parameters Cr A Height 111,5cm, Ha = 124+/- 5.20 (SDS = -2.44) increased, Weight = 26.7 kg, Wh = 18.66+/-2.53, BMI = 21.67 highlight a rapid weight gain; the hypercaloric diet administered by the mother contains 2000 calories instead of 1400-1500 calories and this led to an accelerated increase in weight. Sleep disorders were present, which highlighted a mixed form of apnea / hypopnea with AHI = 404. Biological hypercholesterolemia. In September 2015, seven months after surgery, the patient is 7 years and 5 mo with the same Height 111.5 cm, increased Weight 30.5 kg, BMI = 24.75 with, Abdominal perimeter 72.5 cm. A diet excluding concentrated carbohydrates and limitation of those with long period of adsorption was indicated together with increase of physical activity.

Discussions

Craniopharyngioma, benign trough histology but malignant because of relapse rate and location, is a relatively rare tumor in childhood. Adamantinomatous forms can occur at any age but are most common in childhood. As a

location, craniopharyngioma can occur anywhere along the craniopharingeal channel but most cases are located in the region with these frecvcente saddlery and paraselara supraselar (20-41% pure suprasellar and 53-75% sellar and subsellar). Intrasellar localizations are rare (5-7%) (6). Depending on the tumor location and size, time elapsed since the occurrence until symptoms occur varies between 1 week and 372 months (7). Clinical signs include tumor evocative headache by some authors (8) or visual disorders by newer studies (6), memory loss, ataxia and cognitive dysfunction. Our patient presented progressive visual anomalies. Regarding hormonal dysfunction at the time of diagnosis the literature mentions that 85% of patients have between 1 and 3 hormonal dysfunctions (7), with a rate of 35-95% GH, LH / FSH ratio of 38-82 %, 21-26% ACTH, TSH 21-42% and 6-38% diabetes insipidus (6.9). Our patient falls in the cathegory of patients with repeated TSH hormone deficiency and growth hormone according to the evolution of height. Preoperative steroids were administered to prevent hypocortisolism side effects occurring after surgery. Postsurgical, transient diabetes insipidus can be found in 80-100% of children (10), while the percentage of 40-93% children present a permanent form (11,12), compared to adults. Our patient's permanent diabetes insipidus appeared immediately after surgery. Regarding the histological form of the disease, squamous epithelial cells, trabeculae and uneven lumps of "dry keratin" established the adamantinomatous form. The papillary form cell comprises monomorphic masses arranged in polisade. The adamantinomatous form of our patient associates in 70% cases beta catenin mutations (13,14). The most common mutation is found in exon 3. Tumor removal was followed by substitution treatment implementation with Euthyrox, Hydrocortisone and Minirin Melt; under stress (physical, infectious etc.), the indication is to increase the dose of Hydrocortisone. Our patient had a relatively smooth postoperative course, but rapid increase in weight of about 10 kg in six months raised suspicion of diencephalic obesity risk of the metabolic syndrome and cardiovascular complications at an early age. Currently a pharmacological treatment of diencephalic obesity with dextroamphetamine administered at 10 months, maximum 24 at operation, especially in young people, is discussed. Sibutramine has been used as a treatment for obesity achieving a 7-10% weight loss in combination with diet (15). The mechanism of action is to reduce serotonin norepinephrine and dopamine reuptake. Post- intervention, diencephalic obese patients with craniopharyngioma have predominant parasympathetic autonomic nervous system activity. Parasympathetic system induces insulin secretion stimulated by direct action on pancreatic beta cells and promovating adipogenesis. Octreotide, a somatotropin analog was proposed in order to limit insulin secretion. In our case the patient will benefit from diet, exercise and weight monitoring. The risk of recurrence is high according to data from literature. The patient will be monitored three times a year, biologically and AV in order to prevent any recurrence and diencephalic obesity.

Conclusions

Compared with craniopharyngioma with onset in adulthood, children have different clinical, biological and evolutionary features. The patient monitoring should be done by a team of, pediatric endocrinologist, dietician, ophthalmologist, neurologic surgeon and radiologist.

References

1. Müller H. L. (2011). Diagnostics, treatment, and follow-up in craniopharyngioma. Front. Endocrinol. (Lausanne) 2:70.10.3389/fendo.2011.00096
2. Tadanori Tomita; Robin M. Bowman, Craniopharyngiomas in children: Surgical experience at Children's Memorial Hospital, Child's Nervous System. 2005;21(8-9):729-746.
3. Powers CJ1, New KC, McLendon RE, Friedman AH, Fuchs HE, Cerebellopontine angle craniopharyngioma: case report and literature review, Pediatr Neurosurg. 2007;43(2):158-63.
4. Sartoretti-Schefer S1, Wichmann W, Aguzzi A, Valavanis A, MR differentiation of adamantinous and squamous-papillary craniopharyngiomas, AJNR Am J Neuroradiol. 1997 Jan;18(1):77-87.
5. Fjalldal S, Holmer H, Rylander L, et al., Hypothalamic involvement predicts cognitive performance and psychosocial health in long-term survivors of childhood craniopharyngioma, J Clin Endocrinol Metab, 2013;98:3253–3262.
6. Karavitaki N, Brufani C, Warner JT, et al., Craniopharyngiomas in children and adults: systematic analysis of 121 cases with long-term follow-up, Clin Endocrinol (Oxf), 2005;62:397–409.
7. Van Effenterre R1, Boch AL, Craniopharyngioma in adults and children: a study of 122 surgical cases, J Neurosurg. 2002 Jul;97(1):3-11.
8. Weiner HL1, Wisoff JH, Rosenberg ME, Kupersmith MJ, Cohen H, Zagzag D, Shiminski-Maher T, Flamm ES, Epstein FJ, Miller DC, Craniopharyngiomas: a clinicopathological analysis of factors predictive of recurrence and functional outcome, Neurosurgery. 1994 Dec;35(6):1001-10; discussion 1010-1.
9. Sekine S, Shibata T, Kokubu A, Morishita Y, Noguchi M, et al. (2002) Craniopharyngiomas of adamantinomatous type harbor beta-catenin gene mutations. Amer J Pathol 161: 1997–2001.
10. Caldarelli M, Massimi L, Tamburrini G, Cappa M, Di Rocco C. Long-term results of the surgical treatment of craniopharyngioma: the experience at the Policlinico Gemelli, Catholic University, Rome. Childs Nerv Syst. 2005 Aug;21(8-9):747-57. Epub 2005 Jul 2.
11. Elliott RE1, Wisoff JH, Surgical management of giant pediatric craniopharyngiomas, J Neurosurg Pediatr.

2010 Nov;6 (5):403-16. doi: 10.3171/2010.8.PEDS09385.
12. Elliott RE1, Jane JA Jr, Wisoff JH, Surgical management of craniopharyngiomas in children: meta-analysis and comparison of transcranial and transsphenoidal approaches, Neurosurgery. 2011 Sep;69 (3):630-43; discussion 643. doi: 10.1227/NEU.0b013e31821a872d.
13. Buslei R1, Nolde M, Hofmann B, Meissner S, Eyupoglu IY, Siebzehnrübl F, Hahnen E, Kreutzer J, Fahlbusch R, Common mutations of beta-catenin in adamantinomatous craniopharyngiomas but not in other tumours originating from the sellar region, Acta Neuropathol. 2005 Jun;109(6):589-97. Epub 2005 May 13.
14. Oikonomou E1, Barreto DC, Soares B, De Marco L, Buchfelder M, Adams EF, Beta-catenin mutations in craniopharyngiomas and pituitary adenomas, J Neurooncol. 2005 Jul;73(3):205-9.
15. Danielsson P1, Janson A, Norgren S, Marcus C, Impact sibutramine therapy in children with hypothalamic obesity or obesity with aggravating syndromes, J Clin Endocrinol Metab. 2007 Nov;92(11):4101-6. Epub 2007 Aug 28.

Correspondence to:
Otilia Marginean
"Victor Babes" University of Medicine and Pharmacy,
Department of Pediatrics
2 Eftimie Murgu 300041
Timisoara, Romania
E-mail: omarginean@ymail.com

ERRATUM

Retraction note: *"Determination and isolation of biomarkers in fetal anencephaly by chip-based nanoelectrospray ionization tandem mass spectrometry"*

The article "*Determination and isolation of biomarkers in fetal anencephaly by chip-based nanoelectrospray ionization tandem mass spectrometry*", published in Jurnalul Pediatrului, Year XIV, Vol. XIV, Nr. 53-54, january-june 2011, pp 17-20, was retracted on demand by the corresponding author and with the written consent of all the other authors of the manuscript.

Request to: Jurnalul Pediatrului

Retraction note: *"Determination and isolation of biomarkers in fetal anencephaly by chip-based nanoelectrospray ionization tandem mass spectrometry"*

The authors of the paper entitled "*Determination and isolation of biomarkers in fetal anencephaly by chip-based nanoelectrospray ionization tandem mass spectrometry*", published in Jurnalul Pediatrului, Year XIV, Vol. XIV, Nr. 53-54, january-june 2011, pp 17-20, kindly asks the journal "Jurnalul Pediatrului" to retract this manuscript (HTML and PDF version). This retraction/removal procedure is in compliance with this journal policy.

F. Capitan (corresponding author) I AGREE (DE ACORD)

C. Ilie I agree (De acord)

I. Velea I agree (De acord)

CM. Popoiu I agree (De acord)

ES. Boia I agree (De acord)

C. Schiopu I agree (De acord)

Profesor Dr. ILIE CONSTANTIN
medic primar pediatrie
medic primar neonatologie
cod 742333

Conf. Dr. VELEA IULIAN
medic primar pediatru
endocrionologie, diabet pediatric
Cod 343478

23.12.2015

MANUSCRIPT REQUIREMENTS

The manuscript must be in English, typed single space, one column on A4 paper, with margins: top – 3 cm, bottom – 2,26 cm, left – 1,5 cm, right – 1,7cm. A 10-point font Times New Roman is required.

The article should be organized in the following format: Title, Names of all authors (first name initial, surname), Names of institutions in which work was done (use the Arabic numerals, superscript), Abstract, Keywords, Text (Introduction, Purpose, Materials and Methods, Results, Discussions and/or Conclusions), References, and first author's correspondence address.