FUTURE PROSPECTS IN THE TREATMENT OF PEDIATRIC BURNS. A REVIEW OF THE NILE TILAPIA DERIVED BIOLOGICAL OPTIONS FOR TREATING SUPERFICIAL PARTIAL THICKNESS BURNS

B Ciornei[1,2*], VL David[1,2], ES Boia[1,2]

Abstract

Burn wounds represent one of the hardest to tackle traumatic pathologies for medical systems around the world, but more so for the small patients. WHO estimates that around 11 milion people worldwide are affected by burns, out of which 180,000 die annualy because of these incidents. The treatment is complex, both medical and surgical, firstly by trying to eliminate the cause and spread of the causal agent and to restore biological vital functions. The second part concentrates on infection prevention, cleaning the burn site of any debries resulted from the trauma and last to restore devitalized tissue. The Nile Tilapia is a subspecies of fish from the Tilapia family, with a vast habitat in Africa, that ranges from Egipt to the central african continent, and even Israel. The interest for the use of Nile Tilapia skin for the treatment of burnt wounds has increased in the last 15 years, due to the fact that it's properties have been studies across this time and the need for better and cheaper options has always existed. Today partial thickness burn wounds are treated by the use of silver sulfadiazine and mafenide acetate solutions, whilst in our clinic we use an ointment based on plants cleared for human use. This article's purpose is to present a promising candidate for the regenerative treatment of the skin after burn trauma, through the use of a biological compound found in the skin of the Nile Tilapia (Oreochromis Niloticus). Fish origin collagen and peptides have been studied *in vitro* in regards to their potential for healing stab or burnt wounds. The focus of these studies has been put to *in vitro* use of a combination of prohealing substances, mainly chitosan and electrospining marine peptides derived from tilapia collagen. The use of Nile tilapia skin as a whole, has been timidly used experimentaly, with a single brazilian contingent of researchers performing them. They have conducted their experiments on murine models, a randomized control trial on 30 children and an ongoing phase III clinical trial on adult subjects. In conclusion the use of Nile Tilapia skin or biological compounds like chitosan and marine peptides hydrogels, in the treatment of skin burns is still at the begining. Studies show promising results, but there is a need for more evidence that it really does have an impact on the socio-economic and medical aspect of burn wound treatment.

Keywords: partial-thickness burns, Nile Tilapia, Chitosan, Marine peptide hydrogel

Introduction

Burn wounds represent one of the hardest to tackle traumatic pathologies for medical systems around the world, but more so for the small patients. WHO estimates that around 11 milion people worldwide are affected by burns, out of which 180,000 die annualy because of these incidents [1]. Burns can be caused by objects or substances that release heat, either by friction, through electric energy, radiation exposure or by exogen chemical reaction. The classification of burn trauma takes into account Total Body Surface Area (TBSA) as well as depth of penetration (Fig. 1) [2].

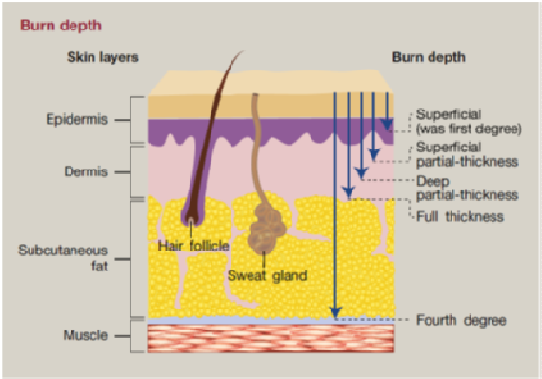

Fig.1. Diagram of burn depth assesment.
Johnson C. Management of burns, Surg. (United Kingdom), vol. 36, no. 8, pp. 435–440, 2018.

[1]"Victor Babes" University of Medicine and Pharmacy, Department of Pediatric Surgery and Orthopedics, Timisoara, Romania
[2]"Louis Turcanu" Clinical Emergency Hospital for Children Timisoara
* Phd Student
E-mail: ciornei91@gmail.com, david.vlad@umft.ro, boiaeugen@yahoo.com

The treatment is complex, both medical and surgical, firstly by trying to eliminated the cause and spread of the causal agent and to restore biological vital functions. The second part concentrates on infection prevention, cleaning the burn site of any debries resulted from the trauma and last to restore devitalized tissue. An additional part would be the management of wound healing complications such as keloid scar or any other aquired deformities [3].

This article's purpose is to present a promising candidate for the regenerative treatment of the skin after burn trauma, through the use of a biological compound found in the skin of the Nile Tilapia (Oreochromis Niloticus). Classical methods are vast, and range from using ointments derived from plants, to surgical transplantation of allograft skin, to synthetic analogs of extracellular matrix, or even transplantation of skin cultured from stem cells in a Petri dish. All have benefits and pitfalls, but the most common denominator is the high cost, that is prohibitive for most medical systems [4-7].

The Nile Tilapia

The Nile Tilapia is a subspecies of fish from the Tilapia family, with a vast habitat in Africa, that ranges from Egipt to the central african continent, and even Israel. They are freshwater fish that tolerate muddy waters, with a varying temperature scale that ranges from 8 to 42 degrees Celsius. They have a life cicle of about 9 years, adults can reach around 4,3 Kgs and 60 cm in lenght. The Nile Tilapia is an omnivorous fish, that feeds on plancton and aquatic plants [8]. Studies have shown that it's use can even spread to other areas of applicability, because of it's high capacity for the consumption of Anopheles mosquitos [9].

The interest for the use of Nile Tilapia skin for the treatment of burnt wounds has increased in the last 15 years, due to the fact that it's properties have been studies across this time and the need for better and cheaper options has always existed. Today partial thickness burn wounds are treated by the use of silver sulfadiazine and mafenide acetate solutions, whilst in our clinic we use a ointment based on plants cleared for human use. These solutions are of great help in determining the wound to heal itself, but are lacking in biological content, thus the wound can heal and close, but in a matter that does not resemble prior status, forming keloid scar

Promising treatment

Fish origin collagen and peptides have been studied *in vitro* in regard to their potential for healing stab or burnt wounds. The focus of these studies has been put on *in vitro* use of a combination of prohealing substances, mainly chitosan and electrospining marine peptides derived from tilapia collagen. Chitosan is a linear polysaccharide obtained through deacetylation of chitin, a structural element found in the exoskeleton of crustaceans. It's use in the food, agricultural and medical industry has been present since the 1980's. A chitosan based hemostatic has been used by the US military in the wars in Iraq and Afganistan(10–12). Ongoing studies try to make use of this material for the purpose of drug delivery through the skin. Marine derived peptides from tilapia skin collagen, have a similar composition to that of human colagen found in the extracelular matrix of the skin, containing 8 essential aminoacids (AA) and 9 non-essential ones. The benefits of using tilapia collagen derived peptides are good biocompatibility, biologic origin, reduced to no immunogenicity and low price, whilst the disadvanteges take into account that they have a fairly great molecular instability and are prone to bacterial degradation [13,14].

The combination of chitosan and marine peptides derived from tilapia skin collagen has been found to have a sinergistic effect, by stimulating celular proliferation, healing, neovascularisation of experimental wound and decreased inflamatory response from the host body. Furthermore studies have shown an antibacterial effect of chitosan/MP compound against E.coli and Staphylococcus aures, recognizing its antibacerial properties and making it a promising tool in the treatment of wound healing [11,15,16]

Other options are focused on the use of allografts and xenografts, which seem to have the same outcome in regards to healing [17,18]. The use of Nile tilapia skin as a whole, has been timidly used experimentaly, with a single brazilian contingent of researchers performing them. They have conducted their experiments on murine models, a first single case report, a randomized control trial on 30 children and an ongoing phase III clinical trial on adult subjects.

In the murine model authors report better adherence of the skin graft to the wound bed, less inflamatory response cells and consecutively better and faster healing compared to the control groups [19]. Based on their prior findings they have atempted the same treatment, in a case study, to a 3 year-old boy admitted to their facillity for a superficial partial thickness scald burn on the face, neck, thorax, abdomen and left arm (Fig.2). Their results reveal a good adherence of the fish skin to the wound, no infectious episodes, less dressing changes and less pain medication needed [20].

Thus an RCT study has been launched by the same facility which included a number of 30 children aged 2-12 years old (15 tests and 15 controls). The subject were randomly atributed to the test or control group. In the test group they had undergone a tilapia skin treatment and in the control group subject were treated conservatively with a 1% siver sulfadiazine cream solution. The results revealed less time spent with dressing changes, less pain medication, less need for anesthesia, but it also showed no significant difference in hospital stay and no differences in regards to time to full wound healing [21].

Fig. 2. A. Aspect of burnt area preop B. Removalof necrotic tissue and blister show a superficial partial thicknes burn C. Apllication of tilapia skin graft to burnt area D. After six days the dressing has been removed showing godd adherence to the whound bed E. Removal of the tilapia skin after 10 days showing complete re-epithelization F. 1 week after dressing removal (Costa BA, Lima Júnior EM, de Moraes Filho MO, Fechine FV, de Moraes MEA, Silva Júnior FR, et al. Use of Tilapia Skin as a Xenograft for Pediatric Burn Treatment: A Case Report. J Burn

Future perspectives

Burn trauma management today, still hasn't found a way of dealing with some aspects of skin regeneration after burns. Researchers experimenting with this treatement must also answer questions regarding the long term outcome of the newly formed skin, what happens with the anexes of the skin, does hair grow back, do sweat glands still participate in the perspiration process, are there any potential malignant threaths?

Conclusions

In conclusion the use of Nile Tilapia skin or biological compounds like chitosan and marine peptides hydrogels, in the treatment of skin burns is still at the begining. Studies show promising results, but there is a need for more evidence that it really does have an impact on the socio-economic and medical aspect of burn wound treatment.

References

1. World Health Organization. Burns, Fact sheet N°365. April 2014. 2014.
2. Johnson C. Management of burns. Surg (United Kingdom) [Internet]. 2018;36(8):435–40. Available from: https://doi.org/10.1016/j.mpsur.2018.05.004
3. Grosfeld JL, O'Neill JA, Fonkalsrud EW, Coran AG. Pediatric Surgery. 2006.
4. Seth AK, Friedstat JS, Orgill DP, Pribaz JJ, Halvorson EG. Microsurgical Burn Reconstruction. Clin Plast Surg [Internet]. 2017;44(4):823–32. Available from: http://dx.doi.org/10.1016/j.cps.2017.05.014
5. Fredman R, Katz AJ, Hultman CS. Fat Grafting for Burn, Traumatic, and Surgical Scars. Clin Plast Surg [Internet]. 2017;44(4):781–91. Available from: http://dx.doi.org/10.1016/j.cps.2017.05.009
6. Ghieh F, Jurjus R, Ibrahim A, Geagea AG, Daouk H, El Baba B, et al. The Use of Stem Cells in Burn Wound Healing: A Review. Biomed Res Int. 2015;2015.
7. Strong AL, Neumeister MW, Levi B. Stem Cells and Tissue Engineering: Regeneration of the Skin and Its Contents. Clin Plast Surg [Internet]. 2017;44(3):635–50. Available from: http://dx.doi.org/10.1016/j.cps.2017.02.020
8. Job BE, Antai EE, Otogo GA, Ezekiel HS. Proximate Composition and Mineral Contents of Cultured and Wild Tilapia (Oreochromis niloticus) (Pisces : Cichlidae) (Linnaeus , 1758). 2015;14(4):195–200.
9. Abebe A, Natarajan P, Getahun A. Efficacy of tilapia, Oreochromis niloticus and Tilapia Zilli for the control of mosquito larvae around Fincha Valley, Oromia region, Ethiopia. 2018;5(3):35–41.
10. Muñoz I, Rodríguez C, Gillet D, M. Moerschbacher B. Life cycle assessment of chitosan production in India and Europe. Int J Life Cycle Assess. 2018;
11. Bhattarai N, Gunn J, Zhang M. Chitosan-based hydrogels for controlled, localized drug delivery. Advanced Drug Delivery Reviews. 2010.
12. Zhang YJ, Gao B, Liu XW. Topical and effective hemostatic medicines in the battlefield. Int J Clin Exp Med. 2015;

13. Hu Z, Yang P, Zhou C, Li S, Hong P. Marine collagen peptides from the skin of Nile Tilapia (Oreochromis niloticus): Characterization and wound healing evaluation. Mar Drugs. 2017;15(4).
14. Wu CJ, Chai HJ, Li JH, Huang HN, Li TL, Chan YL, et al. Effects of sizes and conformations of fish-scale Collagen peptides on facial skin qualities and transdermal penetration efficiency. J Biomed Biotechnol. 2010;2010.
15. Ouyang QQ, Hu Z, Lin ZP, Quan WY, Deng YF, Li SD, et al. Chitosan hydrogel in combination with marine peptides from tilapia for burns healing. Int J Biol Macromol [Internet]. 2018;112:1191–8. Available from: https://doi.org/10.1016/j.ijbiomac.2018.01.217
16. Zhou T, Wang N, Xue Y, Ding T, Liu X, Mo X, et al. Electrospun tilapia collagen nanofibers accelerating wound healing via inducing keratinocytes proliferation and differentiation. Colloids Surfaces B Biointerfaces [Internet]. 2016;143:415–22. Available from: http://dx.doi.org/10.1016/j.colsurfb.2016.03.052
17. Hermans MHE. Porcine xenografts vs. (cryopreserved) allografts in the management of partial thickness burns: Is there a clinical difference? Burns. 2014;
18. Chiu T, Burd A. “Xenograft” dressing in the treatment of burns. Clin Dermatol. 2005;
19. Lima-Junior EM, Picollo NS, Miranda MJB De, Ribeiro WLC, Alves APNN, Ferreira GE, et al. Uso da pele de tilápia (Oreochromis niloticus), como curativo biológico oclusivo, no tratamento de queimaduras. Rev Bras Queimaduras. 2017;
20. Costa BA, Lima Júnior EM, de Moraes Filho MO, Fechine FV, de Moraes MEA, Silva Júnior FR, et al. Use of Tilapia Skin as a Xenograft for Pediatric Burn Treatment: A Case Report. J Burn Care Res. 2019;40(5):714–7.
21. Lima Júnior EM, de Moraes Filho MO, Costa BA, Fechine FV, Alves APNN, de Moraes MEA, et al. Pediatric Burn Treatment Using Tilapia Skin as a Xenograft for Superficial-Partial Thickness Wounds: a Pilot Study Authors: J Burn Care Res. 2019;

Correspondence to:

Vlad Laurentiu David,
University of Medicine and Pharmacy’’Victor Babes’’
P-ta Eftimie Murgu no. 2, Timisoara, Romania
E-mail: david.vlad@umft.ro